

Submission to:

Atlas of High Resolution Manometry

Appendix I

HRM data acquisition

Mark Fox MD, MA (Oxon), MRCP

Research Consultant,
University Hospital Zurich,
CH-8091 Zurich,
Switzerland.

Honorary Consultant,
Oesophageal Laboratory,
St. Thomas' Hospital,
London SE1 7EH.
United Kingdom.

Email markfox_2@hotmail.co.uk

Abbreviations

HRM	High resolution manometry
UOS	Upper esophageal sphincter
LOS	Lower esophageal sphincter

Appendix I: Guide to data acquisition

The primary functions of the esophagus are to transport food and fluid from the mouth to the stomach and to prevent reflux of gastric contents. The aim of investigation in patients with esophageal symptoms is to document and understand if, how and why these functions are disturbed, to establish a diagnosis and to guide rational treatment. It is by these standards that the value of conventional and high-resolution manometry should be judged.

High-resolution manometry (HRM) is obtained by pressure sensors spaced at 1cm intervals from the pharynx to the stomach. HRM recordings can be analyzed and presented either as 'line plots' or as a 'spatiotemporal plot': a compact, visually intuitive display of oesophageal function. HRM has advantages in clinical practice. In contrast to conventional manometry a pull-through is not required and shifts of position do not affect the reliability and reproducibility of pressure recordings.¹ As a result, obtaining reliable data is easy and the new challenge is to get the most out of HRM measurements, to become familiar with interpreting the data displayed in spatiotemporal plots and, crucially, to distinguish clinically important abnormalities of motor function from incidental findings that do not disturb esophageal function.

HRM reveals the segmental character of oesophageal peristalsis and the functional anatomy of the EGJ. Even more fundamentally, HRM displays the pressure gradient during bolus transport, the force that directs the movement of food and fluid through the oesophagus and into the stomach.^{2,3} As a result, HRM increases the accuracy with which bolus transport can be predicted from manometry and identifies clinically relevant abnormalities not detected by conventional investigations.^{2,4,5} This is important because esophageal symptoms and mucosal damage are more closely related to failed bolus transport and poor clearance of reflux than abnormal motor function as assessed by conventional manometry.⁶

This section is not intended to duplicate the Sierra Systems' ManoScan 360 Users Guide but rather to be a practical guide to the many options and opportunities that this equipment provides. Some issues have definitive solutions; on others no commitment is necessary and the appropriate approach will be determined on a case-by-case basis according to 'what you need to see'.

Catheter placement

By comparison with conventional manometry finding the correct position for the high-resolution ManoScan 360 catheter is quicker, simpler and more accurate.⁵ The acquisition program instructs the operator to insert the catheter to a depth based on the patient's height. This position is a few centimeters deeper than required to ensure that the gastric reference channel is in the stomach. Passage into the abdominal cavity is confirmed by asking the patient to take a few deep breaths, a maneuver that highlights the pressure inversion point and the position of the diaphragm.[**figure PiP Normal / HH / figure bowed catheter in dilated catheter**] HRM has a significant advantage over conventional techniques for locating the LES in the presence of a large hiatus hernia and / or very weak lower esophageal sphincter.[**figure large HH & weak LOS**] Once passage into the abdomen has been confirmed the catheter is drawn back into position to ensure that it is not bowed within the esophagus. This prevents relative movement in LES position during the study caused by 'straightening out' of the catheter within the lumen.* The ideal position for the catheter is dictated by the depth of the upper and lower esophageal sphincters and the focus of clinical interest. With 36 pressure sensors it is almost always possible to record motor activity from the pharynx to the stomach; however in tall individuals it may be desirable to leave the catheter in a deeper position to study the esophago-gastric junction or to withdraw the catheter to record motor activity in the oropharynx.

If possible several pressure sensors should remain in the stomach to ensure that movement of the EGJ during respiration or position change does not interfere with the gastric reference channel. This allows for greater flexibility in positioning the gastric reference and the *e*Sleeve LES Sensor during analysis. Recent studies demonstrate that the EGJ has three distinct anatomical components: the intrinsic esophageal LES (iLES), the diaphragmatic crura (cLES) and the sling and clasp muscle fibres of the gastric cardia, that interact to form an effective reflux barrier [**figure three component EGJ**].⁷ The latter forms a relatively stable, low-pressure band (often absent in patients with GERD) that extends a few centimeters distal to the cLES. This should be considered if the operator is interested in the structure and structure of the EGJ.

* Although relative movement of the catheter does not lead to loss of data (as with conventional manometry) stable positioning facilitates analysis.

HRM Measurement

ManoScan can be programmed to direct data acquisition according to local preferences; however within this framework the operator remains free to focus on issues of clinical or academic interest. As HRM establishes itself as the new gold standard for the measurement of esophageal motor activity, findings that accurately predict disturbed esophageal function and the presence of symptoms will be defined. However, at present, there is no consensus of opinion as to how these studies should be performed and the clinical impact of HRM has been demonstrated largely in case series.^{4,5} Pending further research and the development of internationally agreed diagnostic criteria, the following provides information that may be of interest to those performing HRM.

Position:

Manometry can be performed in the upright seated and / or lateral decubitus positions (supine is not recommended due to the risk of aspiration). Studies have shown that position change has effects on LES structure and function.⁸⁻¹⁰ In healthy subjects these effects are small; however in patients with GERD it is common to observe separation of the intrinsic LES and diaphragmatic components of the EGJ on moving from the lateral decubitus to the seated position [**figure EGJ separation**]. Reflux occurs more frequently during EGJ disruption and this may contribute to the increased rate of reflux events in the upright position for patients with mild to moderate GERD.¹⁰ Patients with more severe GERD and especially those with a hiatus hernia (i.e.; wide separation of the intrinsic and diaphragmatic LES) usually have an incompetent reflux barrier both standing up and lying down [**figure large HH & weak LES**]. In addition, obesity represents a challenge to the reflux barrier. Central adiposity increases intra-abdominal pressure and the gastro-esophageal pressure gradient, the force that drives reflux. The common combination of obesity and EGJ disruption provides the perfect scenario in which reflux can occur.¹¹

Recent studies in healthy subjects have shown that esophageal function is not stereotyped but adapts in response to the work required to drive food from the pharynx to the stomach.^{8,9} In the supine position, bolus transport is produced almost exclusively by peristaltic contractions; in the upright position, gravity also contributes. Thus, position change from the lateral decubitus to the upright position *increases* peristaltic velocity and *decreases* contractile pressure because less

active work is required for bolus transport [**figure HRM position**].^{8,9} Position change has the same effect on patients with hypertensive esophageal dysmotility and, as a result, performing the study in the lateral decubitus position increases the diagnostic pick-up of manometry for ‘nutcracker esophagus’ and diffuse esophageal spasm.¹² It may be possible to test the significance of hypotensive esophageal dysmotility by the same maneuver. The esophagus has considerable functional reserve in the upright position and even severe hypotensive peristalsis (<30 mmHg) is consistent with normal bolus transport; however this finding is more likely to be clinically relevant if peristalsis fails to respond to the increased workload required for bolus transport on lying down. Thus studying esophageal function in both positions appears to increase the sensitivity of manometry for hypertensive contraction and the specificity of manometry for hypotensive contraction.

Bolus volume and physical characteristics:

Similar to the effects of position, the volume and physical characteristics of food have effects on esophageal workload. Varying the volume of wet swallows between 1 and 20ml has little effect on peristaltic function because small amounts of fluid pass along the length of the esophageal body without distending the lumen.¹³ Drinking larger volumes inhibits peristalsis while swallowing continues but then the esophagus is cleared by a powerful contraction [**figure single swallow vs. drink**]. Distension of the esophagus by volume reflux is also followed by vigorous clearance in healthy subjects, failure to do so is characteristic of severe GERD [**figure water swallow vs. reflux clearance**].

Peristaltic velocity becomes progressively *slower* and contractile pressure *more powerful* as the work required for bolus transport increases from dry (i.e.; no bolus) to fluid swallows, and from fluid to solid bolus swallows [**figure water vs. solid bolus Normal**].⁸ Viscous fluids improve the sensitivity of combined manometry-impedance studies for ‘ineffective esophageal motility’,⁹ and including solid bolus swallows also increases the sensitivity of manometric investigation [**figure water vs. solid bolus DES**].^{8,12} This is important because most patients with ‘endoscopy-negative dysphagia’ experience symptoms on swallowing solids and not fluids.¹² The success of solid bolus transport depends closely on the physical characteristics of the bolus. The consistency of swallowed bread is variable because patients salivate and chew the bolus to different degrees.

In addition bread swallows fragment and usually require repeated swallows to clear from the esophagus.¹⁴ Marshmallow pastilles (or similar) are an alternative that can be swallowed whole and produce more consistent results.^{8, 12} Using this technique in healthy volunteers, concurrent HRM and videofluoroscopy revealed that a wide ‘proximal transition zone’ (poor coordination) between the proximal and mid-distal esophageal contractions is a cause of solid bolus escape [**figure wide TZ solid bolus escape**].⁸ Preliminary evidence suggests that this abnormality can cause functional dysphagia in some patients and impairs esophageal clearance in patients with GERD.^{4, 15} Notwithstanding these findings interpreting the esophageal response to solid swallows without concurrent imaging remains challenging with conventional or high-resolution manometry!

Large volume swallows

In health repeated swallows inhibit esophageal motor activity and the LES allowing food and fluid to pass freely into the stomach. If this does not occur the esophagus rapidly fills up resulting in chest discomfort, dysphagia and regurgitation as seen in patients with achalasia. In a large clinical series reported by Clouse et al., HRM identified several cases of achalasia that had been missed by conventional manometry.⁵ Most of these patients had relatively low LES pressures and were picked-up only on the basis of a raised esophago-gastric pressure gradient, i.e.; intra-esophageal pressure was higher than gastric pressure due to retention of fluid in the esophagus. This measurement is more accurate for the diagnosis of achalasia than ‘point measurements’ of baseline LES pressure or nadir LES pressure on swallowing.² Large volume swallows (>100ml for esophageal studies) increase the sensitivity of this measurement because intra-esophageal pressure is directly proportional to the volume of fluid retained in the esophagus [**figure 10 vs. 200ml swallow: achalasia**]. Large volume swallows also reveal structural as well as functional obstruction to flow [**figure 10 vs. 200ml swallow: structural obstruction**]

Manoscan 360 displays the pressure gradient from the pharynx to the stomach in the panel on the right of the screen. In addition to functional obstruction at the LES, measurement of the pressure gradient are very helpful in detecting functional and structural obstruction across the upper esophageal sphincter (UES). It is well recognized that failure of UES relaxation or the presence of a crico-pharyngeal bar can raise ‘intra-bolus pressure’ in this region. This represents the build

up of pressure proximal to a functional or structural resistance to flow. HRM makes it easy to detect raised intra-bolus pressure and accurately locates the position of the lesion because the maximum intra-bolus pressure gradient occurs at the point of maximum resistance to flow **[figure UES HRM]**.¹⁶ Moreover HRM can help to define the clinical significance of this pathology because a lesion seen on videofluoroscopy is very unlikely to cause swallowing problems if it *does not* increase resistance to flow and co-locate with the maximum pressure gradient. Once again large volume swallows (~20ml for pharyngeal studies) make detection of pathology easier because intra-bolus pressure increases with bolus volume.¹⁶

Provision of a meal and post-prandial recordings

Most patients experience esophageal symptoms not during but after a meal; however manometry is usually performed in the fasted state. Many experience heartburn and acid regurgitation typical of GERD and in these patients pH±MII reflux studies are likely to be positive; however in others the underlying causes are less clear. It can be very revealing to provide a test meal and continue HRM until the patient experiences the symptoms of which he or she complains.

Normal findings after a meal include a small increase in peristaltic velocity and decrease in contractile pressure, changes that may reflect reduced resistance to bolus transport following the characteristic fall in LES pressure and length.⁸ The value of HRM in GERD has not yet been studied; however HRM is at least as accurate as sleeve sensor manometry for the detection of transient LES relaxations **[figure TLESR]** and ‘common cavity’ pressure effects indicative of reflux **[figure Belch and Reflux]**.¹⁷ HRM also demonstrates intermittent separations of the intrinsic and diaphragmatic components of the EGJ during which a high proportion of reflux events in patients with GERD occur **[figure EGJ separation]**.¹⁰ Post-prandial symptoms that do not respond to acid suppression may be related to non-acid reflux or esophageal dysmotility **[figure esophageal shortening and spasm]**, or LES dysfunction. In addition rumination syndrome should always be considered in the differential diagnosis of persistent, treatment resistant ‘heartburn and regurgitation’ or ‘postprandial vomiting’.¹⁸ Patients with rumination are often diagnosed with GERD on the basis of pH studies; however recurrent passage of gastric contents into the oesophagus will result in pathological acid exposure whatever the cause. In contrast manometry is diagnostic and clearly distinguishes rumination (voluntary, but

subconscious abdominal contraction forcing gastric contents into the esophagus) from ‘volume regurgitation’ in GERD (a low pressure event associated with LOS relaxation but not abdominal contraction) and vomiting (high pressure retrograde peristalsis)[**figure rumination vs. reflux**]. Similar behaviour is also found in patients with recurrent belching; a condition in which patients swallow air and then use a variety of subconscious maneuvers including contraction of the abdominal muscles to bring the air back up.¹⁹

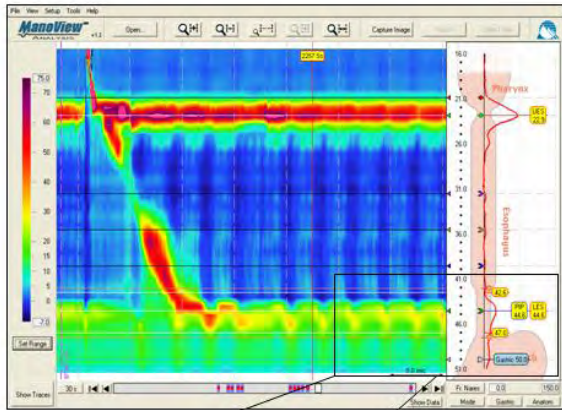
Other maneuvers

Additional tests of EGJ integrity include raising the gastro-esophageal pressure gradient by straining, voluntary leg-raise, forceful coughing or the Valsalva and Mueller maneuvers [**figure EGJ maneuvers**]. A variety of tests have also been described to trigger esophageal dysfunction and symptoms including the acid perfusion (Bernstein) test and the edrophonium (Tensilon) test. The clinical value of observations made during provocation tests is less convincing than those made during ambulatory investigation or physiologic ‘experiments’ (e.g. a test meal); nevertheless these procedures may be valuable in certain situations. Therapeutic trials of medications (e.g.; nitrate donors) have also been applied to assess the manometric and symptomatic response of peristaltic or LES function [**figure therapeutic trial**].

Summary:

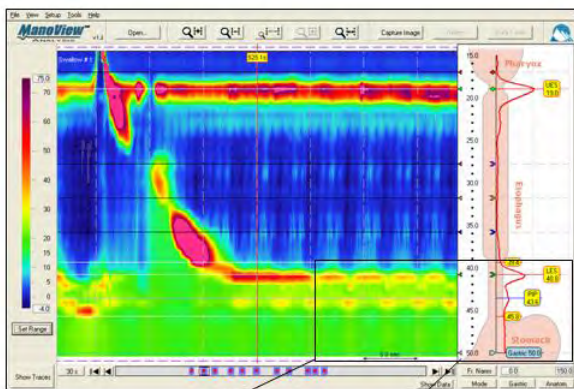
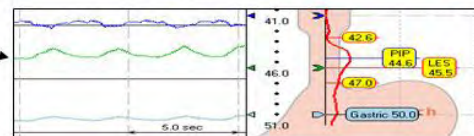
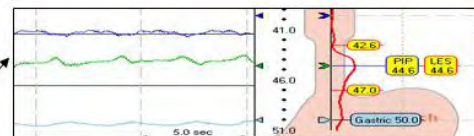
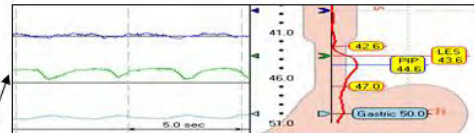
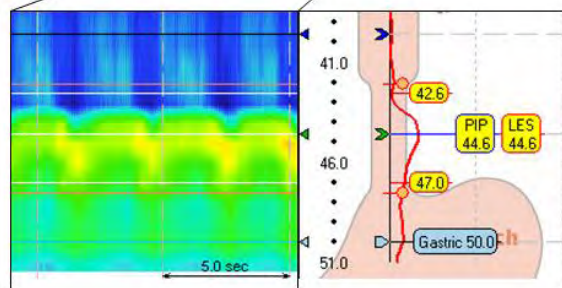
HRM has advantages over conventional manometry that improve the reliability and diagnostic accuracy of investigation. The challenge is to identify abnormal motor activity that causes symptoms and impairs esophageal function. Meaningful results are most likely to be obtained when symptoms occur. The limitation of traditional, stationary manometry studies is that symptoms are rarely triggered by water swallows in the upright position in fasted patients. Patients with GERD most often experience symptoms after meals and other events that challenge the reflux barrier. Swallowing difficulties are most commonly experienced with solid food and on lying down. This section described the effect of position change, bolus characteristics and straining on esophageal function. Symptoms and esophageal dysfunction that occur during ‘physiologic provocation’ has greater validity than those triggered by experimental provocation. In the past the detail provided by conventional manometry was not sufficient to describe the

response to these events. HRM provides more and more revealing information about esophageal motor function and combining this technique with physiologic challenge may increase further the sensitivity and clinical relevance of manometry in patients with GERD and swallowing difficulties.



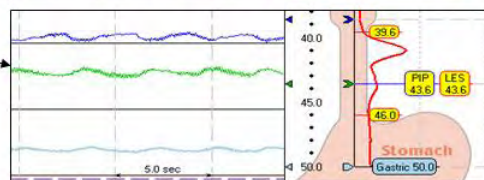
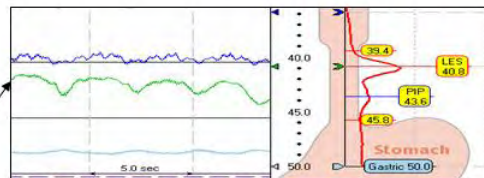
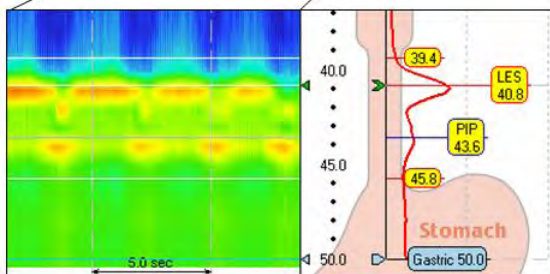
**Figure pressure inversion point:
Normal subject**

On inspiration the pressure falls in the thorax and rises in the abdomen. The EGJ is represented by a single pressure band. The pressure inversion point is located within this band at the transition between the two body cavities.



**Figure pressure inversion point:
Large hiatus hernia**

The EGJ is represented by a double pressure band about 4cm apart. The distal band pressure (diaphragmatic LES) increases in inspiration and decreases in expiration. Reciprocal changes are seen in the proximal pressure band (intrinsic LES). The pressure inversion point is located at the distal band (i.e.; the diaphragm)



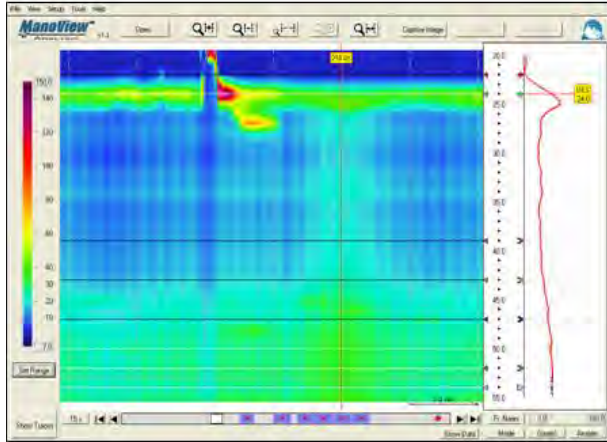


Figure bowed catheter in dilated esophagus

Achalasia patient with gross dilation of esophagus.

The UES is visible. The EGJ is not seen even on inspiration. Respiratory effort and swallowing has a uniform effect on pressure throughout the recording (i.e.; the catheter is coiled in esophagus). Pressure increases from proximal to distal due to increasing hydrostatic pressure within a standing column of esophageal contents.

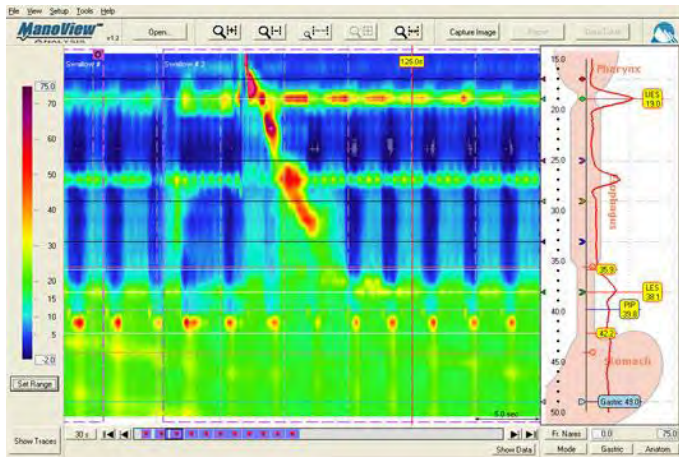


Figure hiatus hernia / weak LES in patient with ineffective peristalsis and severe GERD

A 5cm hiatus hernia is present and the reflux barrier is very weak. The diaphragmatic LES forms a pressure band seen only on inspiration (the diaphragmatic 'pinch'). The intrinsic LES is only seen during expiration and is augmented during a short post-contraction. It would be extremely difficult to locate the correct position for pH electrode using conventional manometry.

Version 2

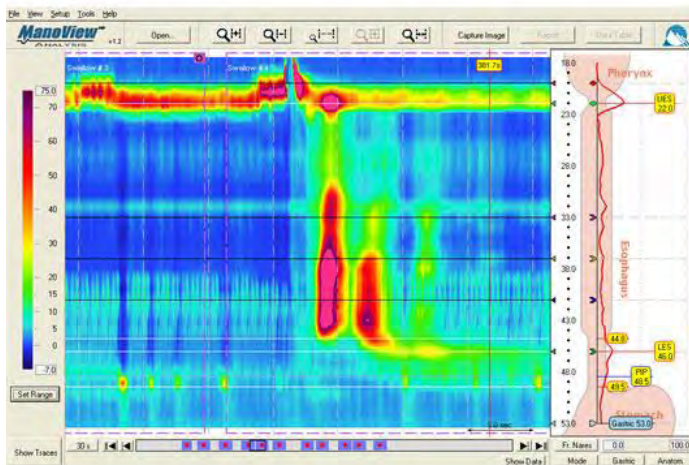


Figure hiatus hernia / weak LES in patient with diffuse esophageal spasm

A hiatus hernia is present however the reflux barrier is very weak. The diaphragmatic 'pinch' is seen on inspiration; however the intrinsic LES is only seen during a short post-contraction. It would be extremely difficult to locate the correct position for pH electrode using conventional manometry.

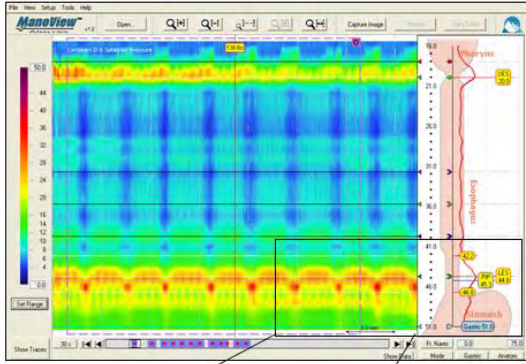


Figure: Three EGJ components

The intrinsic LES (iLES) and the diaphragmatic crura (cLES) move with respiration and changes in pressure reciprocate to maintain an effective reflux barrier. The sling and clasp muscle fibres of the gastric cardia form a stable, low-pressure band extending below the diaphragm (here more prominent than usual) that does not move with respiration. This band is often missing in patients with GERD probably because of structural changes at the EGJ.

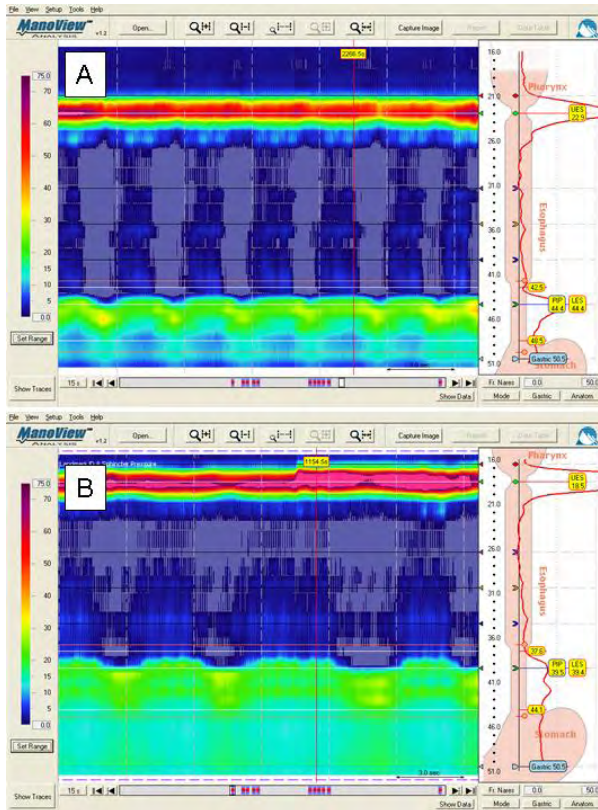
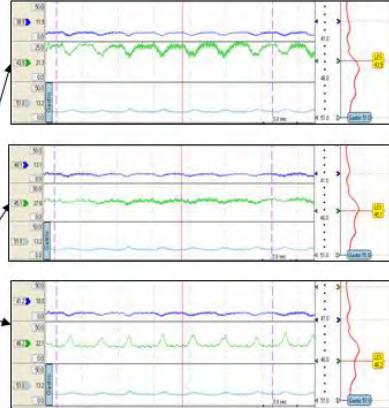
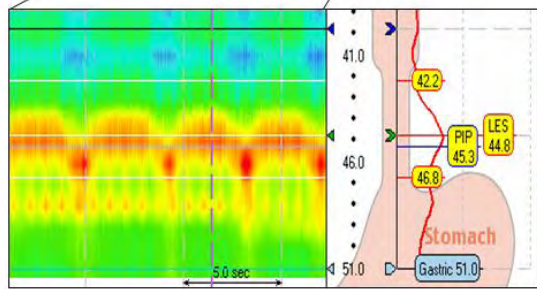


Figure EGJ separation

GERD patient in:
 A: right lateral decubitus position
 B: upright, seated position

Note EGJ movement with respiration.

A: In the lateral decubitus position the reflux barrier is 'intact'. The right panel reveals a single pressure peak at the EGJ.

B: In the upright position there is separation of the intrinsic (iLES) and diaphragmatic, crural (cLES) components of the EGJ. The right panel reveals a double pressure peak ('double bump')

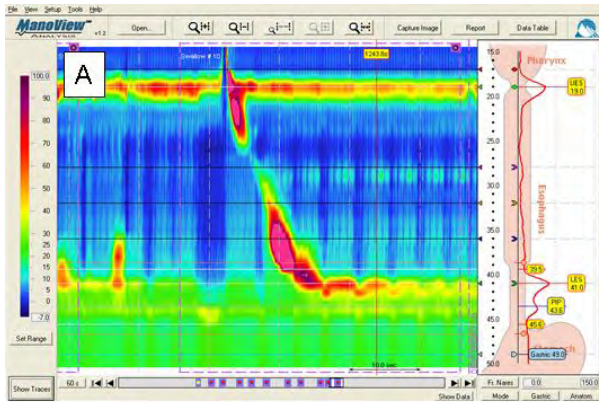


Figure single swallow vs. drink

GERD patient representative:
 A: single 10ml water swallow
 B: repeated water swallow

Single water swallow in the upright position requires little work to transport and the mid-esophageal contraction is weak.

Repeated water swallows inhibit esophageal peristalsis and LES function; however on the final swallow a powerful contraction takes place to clear the esophagus. Note the smooth, well-coordinated transition between proximal and mid-esophageal peristalsis and increased contractile pressure in the smooth muscle esophagus.

Also note the 4cm hiatus hernia.

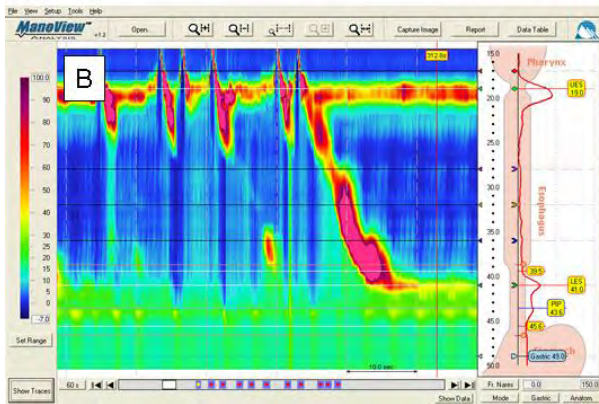
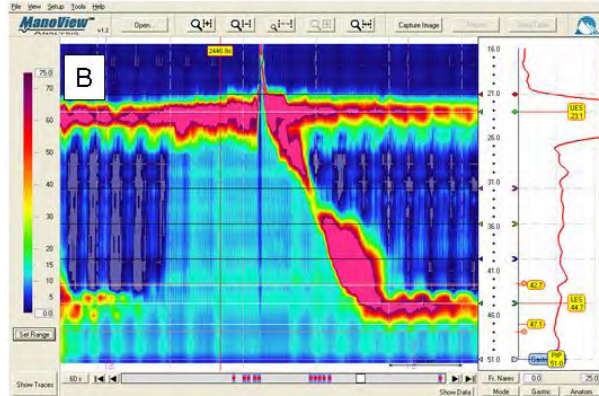
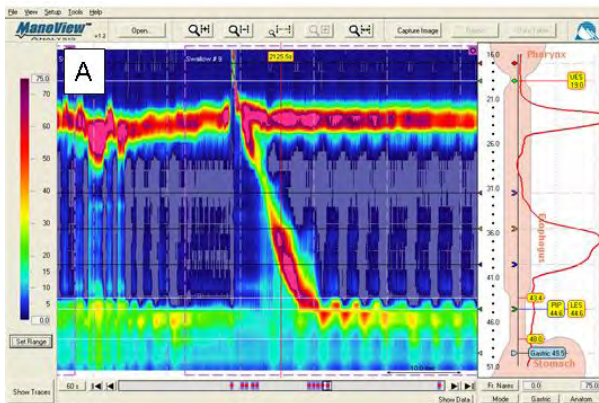


Figure water swallow vs. reflux

Normal patient representative:
 A: normal water swallow
 B: reflux cleared by swallow

A single water swallow requires little work to clear whereas volume reflux requires vigorous clearance. Increased esophageal work is reflected in slower peristaltic velocity and higher contractile pressure.

HRM identifies the onset of transient LES relaxation and, a few seconds later, the common cavity pressure rise that indicates filling of the esophagus with gastric contents.



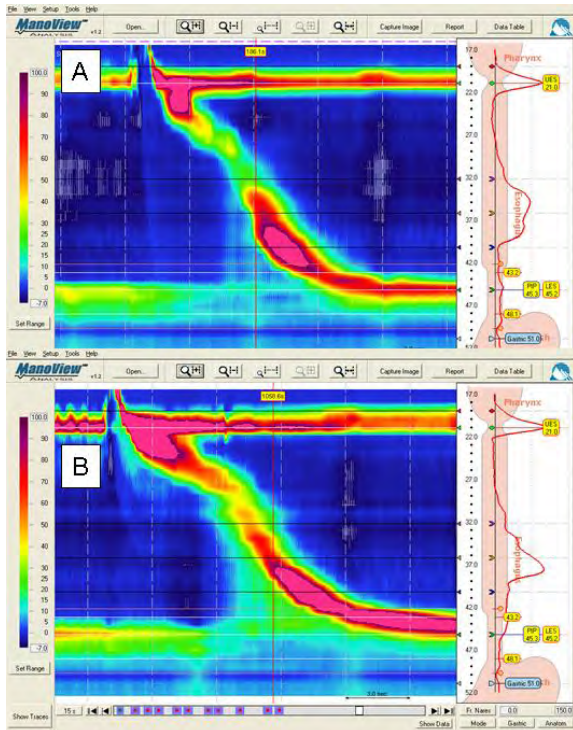


Figure liquid vs. solid bolus

Normal patient representative:
 A: water swallow
 B: bread bolus

The solid bolus swallow has:

1. Higher contractile pressure in every segment with smoother transition between proximal and mid-esophageal peristalsis
2. Slower peristaltic velocity
3. Higher esophago-gastric pressure gradient

All of which reflect increased work for solid bolus transport

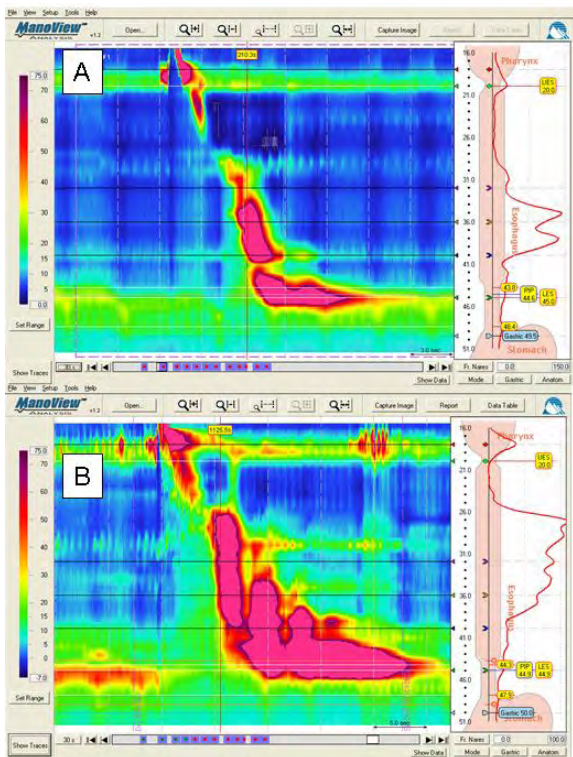


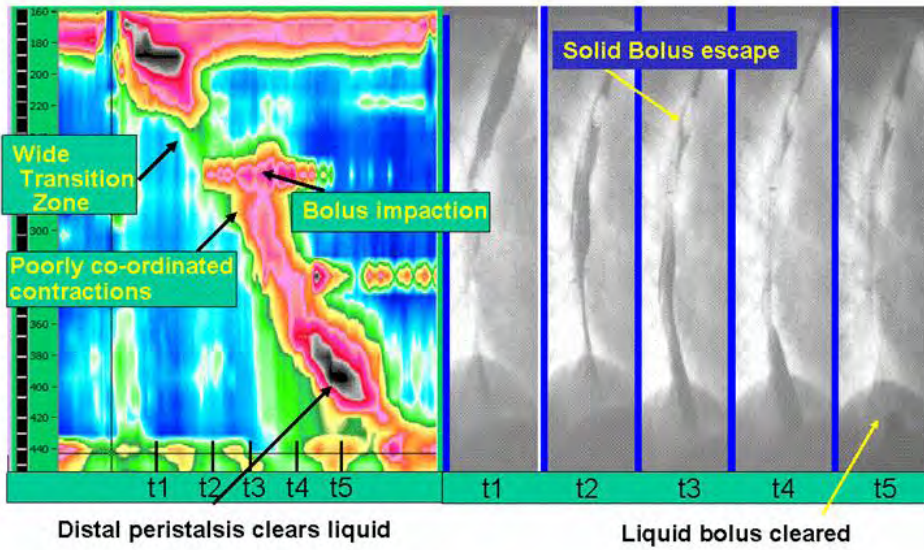
Figure liquid vs. solid bolus reveals esophageal spasm

DES patient representative:
 A: water swallow
 B: bread bolus

Increased work for solid bolus transport increases the sensitivity for the diagnosis of esophageal disorders. Water swallows were within normal limits; however, solid food produced hypertensive, simultaneous and repetitive contractions.

Figure wide TZ - solid bolus escape

Concurrent HRM and videofluoroscopy of solid bolus transport (water perfused 32 channel equipment). A wide proximal transition zone of >3cm is seen on the HRM spatiotemporal plot, the peristaltic contraction is otherwise normal. Concurrent videofluoroscopy reveals solid bolus escape at this level (note the pressure rise at the level of bolus impaction). The liquid barium is transported into the stomach.



Fox et al. APT 2006

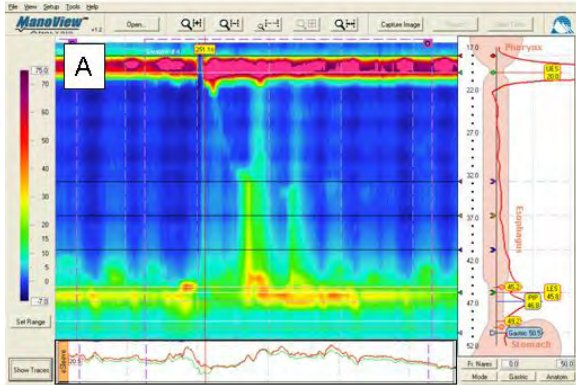


Figure 10ml vs. 200ml swallow: Achalasia

The diagnosis of achalasia was uncertain on conventional testing due to the relatively low LES pressure and partial relaxation (seen on eSleeve recording). HRM confirms the diagnosis by documenting higher pressure in the esophagus than the stomach (i.e.; elevated esophago-gastric pressure gradient (seen in the right panel)). The EGPG is the most sensitive diagnostic marker for achalasia; however it is much easier to appreciate following a large volume swallow which fills the esophageal lumen. This test raises intra-esophageal pressure and reveals severe functional obstruction at the LES.

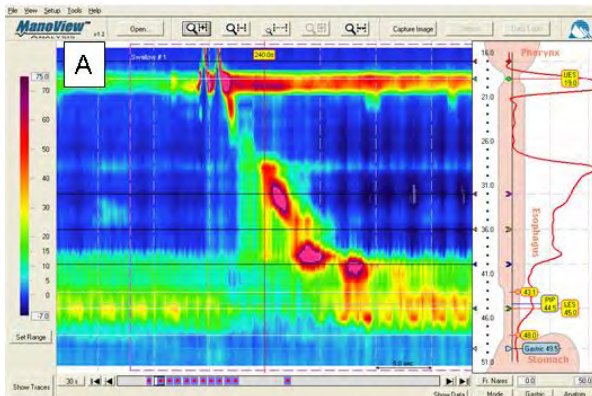
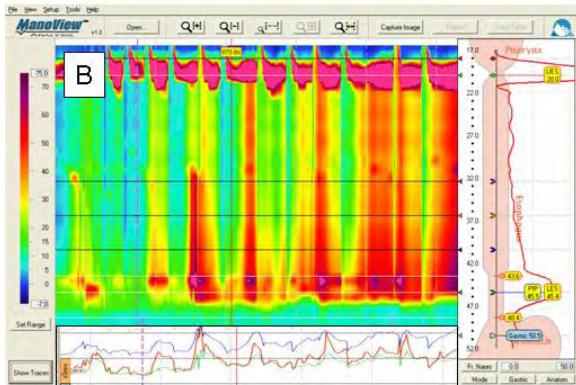


Figure 10ml vs. 200ml swallow: Structural obstruction to flow

This patient with GERD presented with swallowing difficulties. Endoscopy had shown Barrett esophagus without dysplasia.

Normal LES relaxation is present on A: single and B: repeated swallows; however HRM reveals resistance to flow 5cm above the sphincter as evidenced by the sudden drop in intra-bolus pressure. The large volume swallow highlights this by filling the esophagus and further raising intra-bolus pressure. The lesion is structural because there is no persistent high pressure zone at this level. CT was inconclusive but endoscopic ultrasound revealed a submucosal tumor.

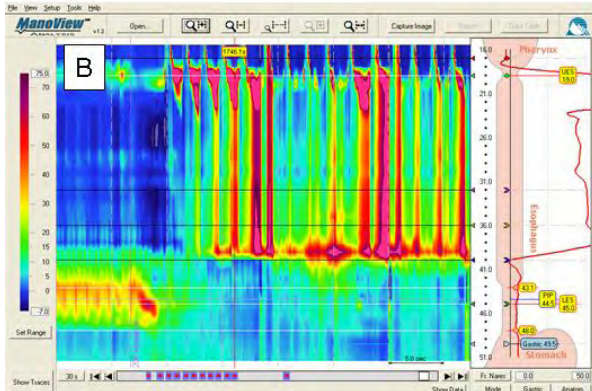
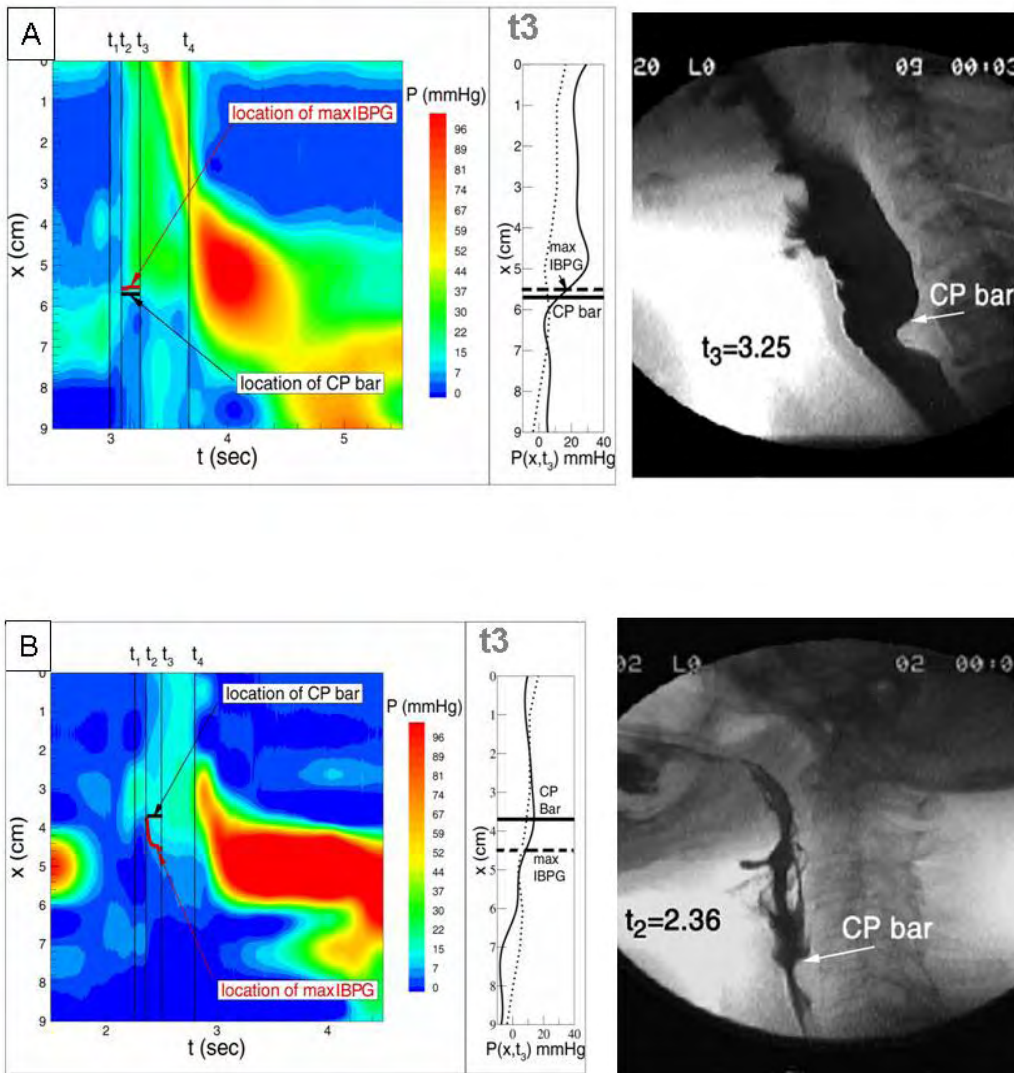


Figure UES HRM

Concurrent HRM and videofluoroscopy of 20ml water swallows (water perfused 21 channel equipment) in two patients with pharyngeal dysphagia.

A: The pharyngeal contraction is normal. There is a sharp drop in intra-bolus pressure in the pharynx (significant intra-bolus pressure gradient (IBPG)). This indicates significant resistance to flow and imaging reveals a crico-pharyngeal (CP) bar at this level.

B: The pharyngeal contraction is weak. There is no sharp drop in intra-bolus pressure at the level of the crico-pharyngeal bar (insignificant intra-bolus pressure gradient (IBPG)). This indicates that there is little resistance to flow at this level and dysphagia is likely due to the 'weak pharyngeal pump'.



Pal et al. AJP 2003

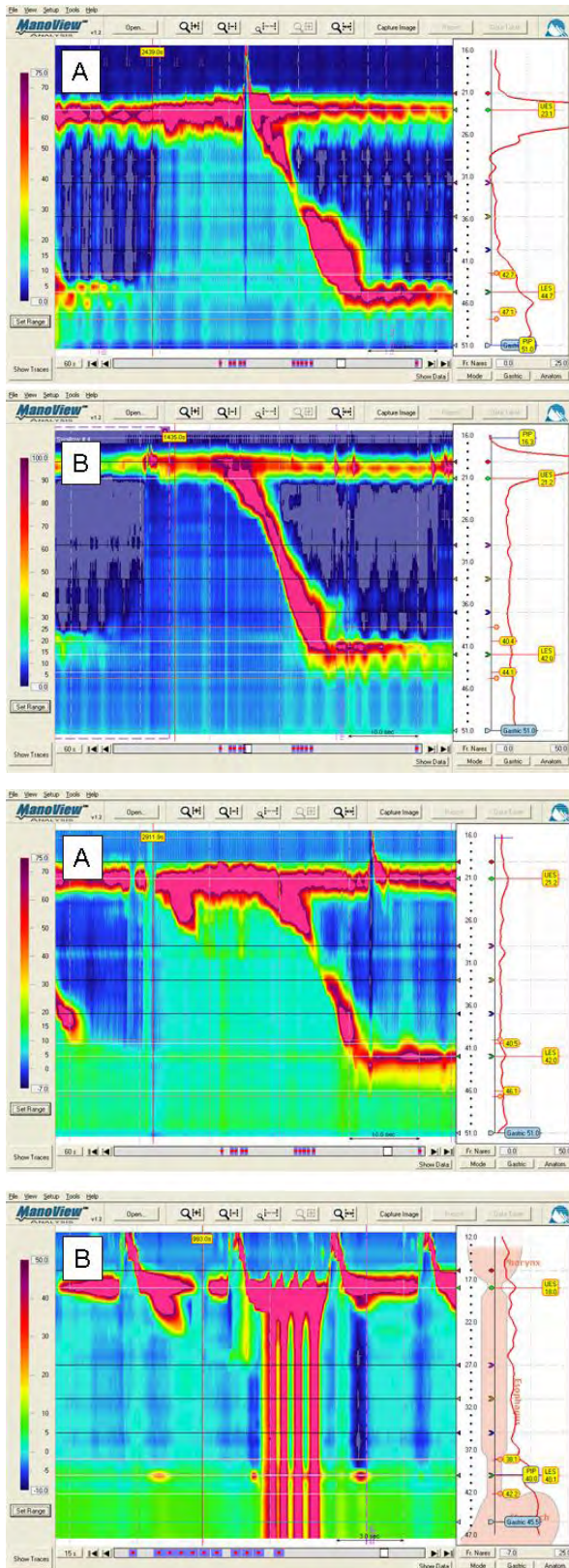


Figure TLESR

The onset of transient LES relaxation is followed a few seconds later by a 'common cavity pressure rise' that indicates filling of the esophagus with gastric contents

- A: reveals the pressure gradient after sphincter relaxation has occurred but before the sphincter has opened (reflux cleared by voluntary swallow).
- B: reveals equilibration of pressure through the open sphincter: 'a common esophago-gastric cavity' (reflux cleared by secondary peristalsis).

Figure: Belch and Extra-esophageal reflux.

A: Transient LES relaxation with reflux increases intra-esophageal pressure to the level of gastric pressure and this can trigger reflex UES relaxation. There is equilibration of pressure from pharynx to stomach (venting / belching) but no gastro-esophageal pressure gradient thus reflux cannot occur.

B: LES pressure is very weak and there is a positive gastro-esophageal pressure gradient at the time of UES relaxation / belching allowing extra-esophageal reflux to occur. A few seconds later the patient coughs.

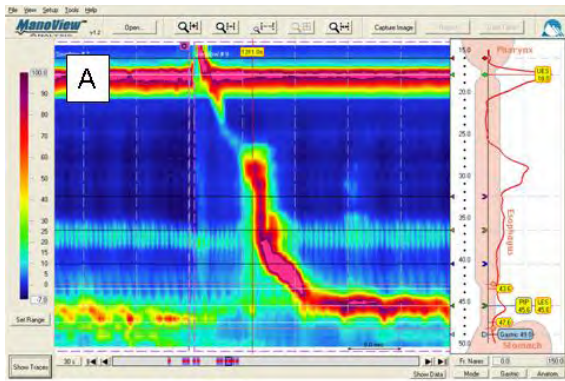
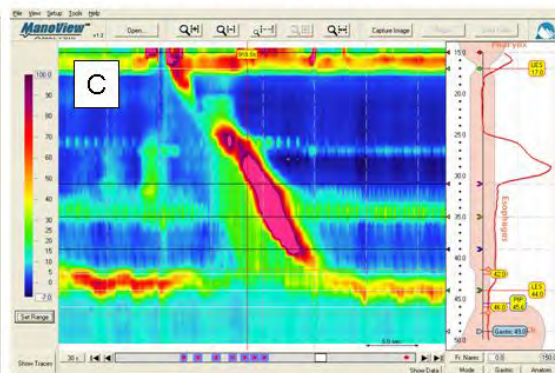
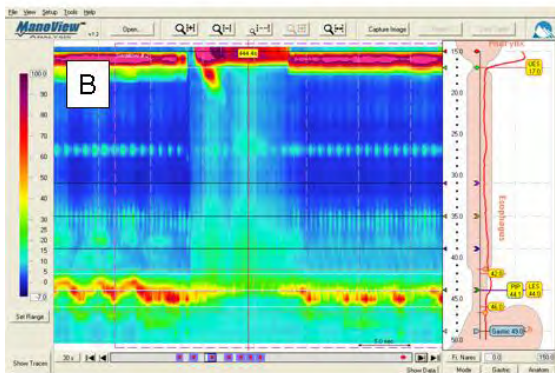


Figure: Therapeutic trial in esophageal spasm

This patient complained of chest pain on swallowing and dysphagia. These symptoms occurred on focal spasm affecting the mid-esophageal segment (A). Nitrates were not tolerated; however sildenafil (extends action of endogenous nitric oxide) relieved symptoms. On water swallows esophageal peristalsis was completely inhibited (B); however *normal* peristalsis was present for large volumes and solids (C). Indicates that nitric oxide increases threshold stimulus required for peristalsis to be triggered).



References

1. Nayar DS, Khandwala F, Achkar E, Shay SS, Richter JE, Falk GW, Soffer EE, Vaezi MF. Esophageal manometry: assessment of interpreter consistency. *Clin Gastroenterol Hepatol* 2005;3:218-24.
2. Staiano A, Clouse RE. Detection of incomplete lower esophageal sphincter relaxation with conventional point-pressure sensors. *Am J Gastroenterol* 2001;96:3258-67.
3. Ghosh SK, Pandolfino JE, Zhang Q, Jarosz A, Shah N, Kahrilas PJ. Quantifying esophageal peristalsis with high-resolution manometry: a study of 75 asymptomatic volunteers. *Am J Physiol Gastrointest Liver Physiol* 2006;290:G988-97.
4. Fox M, Hebbard G, Janiak P, Brasseur JG, Ghosh S, Thumshirn M, Fried M, Schwizer W. High-resolution manometry predicts the success of oesophageal bolus transport and identifies clinically important abnormalities not detected by conventional manometry. *Neurogastroenterol Motil* 2004;16:533-42.
5. Clouse RE, Staiano A, Alrakawi A, Haroian L. Application of topographical methods to clinical esophageal manometry. *Am J Gastroenterol* 2000;95:2720-30.
6. Tutuian R, Castell DO. Combined multichannel intraluminal impedance and manometry clarifies esophageal function abnormalities: study in 350 patients. *Am J Gastroenterol* 2004;99:1011-9.
7. Brasseur JG, Ulerich R, Dai Q, Patel D, Soliman A, Miller LS. Pharmacological Dissection of the Gastro-Oesophageal Segment into Three Sphincteric Components. *J Physiol* 2006;(in press).
8. Fox M, Fried M, Menne D, Stutz B, Schwizer W. The effect of tegaserod on esophageal function: a randomized controlled trial in healthy volunteers *Aliment Pharmacol Ther* 2006;24:1017-1027.
9. Tutuian R, Elton JP, Castell DO, Gideon RM, Castell JA, Katz PO. Effects of position on oesophageal function: studies using combined manometry and multichannel intraluminal impedance. *Neurogastroenterol Motil* 2003;15:63-7.
10. Bredenoord AJ, Weusten BL, Timmer R, Smout AJ. Intermittent spatial separation of diaphragm and lower esophageal sphincter favors acidic and weakly acidic reflux. *Gastroenterology* 2006;130:334-40.
11. Pandolfino JE, El-Serag HB, Zhang Q, Shah N, Ghosh SK, Kahrilas PJ. Obesity: a challenge to esophagogastric junction integrity. *Gastroenterology* 2006;130:639-49.
12. Meshkinpour H, Eckerling G. Unexplained dysphagia: viscous swallow-induced esophageal dysmotility. *Dysphagia* 1996;11:125-8.
13. Srinivasan R, Vela MF, Katz PO, Tutuian R, Castell JA, Castell DO. Esophageal function testing using multichannel intraluminal impedance. *Am J Physiol Gastrointest Liver Physiol* 2001;280:G457-62.
14. Poudroux P, Shi G, Tatum RP, Kahrilas PJ. Esophageal solid bolus transit: studies using concurrent videofluoroscopy and manometry. *Am J Gastroenterol* 1999;94:1457-63.
15. Janiak P, Ghosh S, Hebbard G, Menne D, Fried M, Thumshirn M, Brasseur J, Schwizer W. Changes in upper esophageal motor function in reflux esophagitis defined by high resolution manometry. *Gastroenterology* 2001;[DDW abstract].

16. Pal A, Williams RB, Cook IJ, Brasseur JG. Intrabolus pressure gradient identifies pathological constriction in the upper esophageal sphincter during flow. *Am J Physiol Gastrointest Liver Physiol* 2003;285:G1037-48.
17. Bredenoord AJ, Weusten BL, Timmer R, Smout AJ. Sleeve sensor versus high-resolution manometry for the detection of transient lower esophageal sphincter relaxations. *Am J Physiol Gastrointest Liver Physiol* 2005;288:G1190-4.
18. Fox M, Young A, Anggiansah A, Anggiansah R, Sanderson J. Interactive case report: A 22 year old man with persistent regurgitation and vomiting *BMJ* 2006;332: 1438, 332: 1496, 333: 133.
19. Bredenoord AJ, Weusten BL, Sifrim D, Timmer R, Smout AJ. Aerophagia, gastric, and supragastric belching: a study using intraluminal electrical impedance monitoring. *Gut* 2004;53:1561-5.
20. Wise JL, Murray JA, Conklin JL. Regional differences in oesophageal motor function. *Neurogastroenterol Motil* 2004;16:31-7.

Submission to:

Atlas of High Resolution Manometry

Appendix II

HRM data analysis

Mark Fox MD, MA (Oxon), MRCP

Research Consultant,
University Hospital Zurich,
CH-8091 Zurich,
Switzerland.

Honorary Consultant,
Oesophageal Laboratory,
St. Thomas' Hospital,
London SE1 7EH.
United Kingdom.

Email markfox_2@hotmail.co.uk

Abbreviations

HRM	High resolution manometry
UOS	Upper esophageal sphincter
LOS	Lower esophageal sphincter

Appendix II: HRM data analysis

The acquisition of reliable data about esophageal motor function is made easy by ManoScan. The next step is to apply the ManoView analysis program to get the most out of these measurements, to distinguish clinically important abnormalities from incidental findings, to establish a definitive diagnosis and to guide rational treatment.

HRM reveals the segmental character of oesophageal peristalsis and the functional anatomy of the EGJ. In addition HRM displays the intra-bolus pressure gradient, the force that directs the movement of food and fluid through the oesophagus and into the stomach.^{1, 2} Both are necessary to appreciate the mechanics of bolus transport. The pattern of esophageal peristalsis and EGJ activity defines whether esophageal motor function is normal or abnormal. The intra-bolus pressure gradient defines whether or not this activity is consistent with esophageal clearance. Combining these two features HRM increases the ability to identify abnormalities of esophageal function that disturb bolus transport.^{1, 3, 4} In addition it is possible to assess whether a weak LES or transient LES dysfunction is likely to predispose to GERD. These features are important because esophageal symptoms and mucosal damage are more closely related to failed bolus transport and poor reflux clearance than abnormal motor function *per se* (at least as assessed by conventional manometry).⁵

This section is intended to compliment Sierra Systems' ManoView Users Guide and to act as a guide to the many options that this program provides. Some issues have definitive solutions; on others no commitment is necessary and the appropriate approach will be determined on a case-by-case basis according to 'what you need to see'.

Data display

High-resolution manometry (HRM) data can be presented and analyzed either as 'line plots' or as a 'spatiotemporal plot' [**figure normal peristalsis**]. Line plots display pressure recordings from individual sensors; the spatiotemporal plot displays pressure from all sensors. For the latter pressure recordings from each individual sensor are interpolated such that there is a smooth (not stepped) transition in pressure from one to the next. Each pressure is assigned a colour across a given range. The data is then displayed in a plot with time on the x -axis and distance from the nose on the y -axis. This provides a compact, visually intuitive display of esophageal function. Almost every aspect of the analysis can be performed semi-automatically or manually as time allows and / or as considered appropriate by the user.

Calibration

First, the data is corrected for the thermal sensitivity by visually identifying the instant when the assembly was pulled from the nose at the end of the recording [**figure calibration**]. Immediately after that instant, the catheter is still at body temperature but all pressure sensors are exposed to atmospheric pressure. The software routine then sets this pressure as zero and applies sensor-specific thermal correction to the entire manometric data set. In addition this *post-hoc* calibration compensates for measurement drift that may have appeared during the study.

Gastric or atmospheric reference

Gastric pressure is recorded by one of the distal sensors. The user can define whether gastric or atmospheric pressure is taken as the reference [**figure reference**]. Gastric pressure is closely related to intra-abdominal pressure and varies between individuals as a function of waist circumference (adiposity).⁶ Gastric pressure also varies in a given individual with respiration, position change and prandial state. Although atmospheric pressure provides a more stable baseline (valuable in research when making comparisons between individuals), gastric pressure provides a more physiologic reference. Peristalsis drives bolus transport into the stomach only if it builds up intra-bolus pressure higher than gastric pressure and reflux occurs only if gastric pressure is higher than that of the EGJ. These issues are relevant in clinical practice because obese patients have high intra-gastric pressure a situation that increases the risk of reflux and may also impair esophageal clearance.⁶

ManoView places the gastric reference below the EGJ. Variation in pressure with respiration is pronounced if the reference is moved close to the diaphragm (deep breathing may even bring the reference sensor into the diaphragmatic EGJ). In addition positions close to the diaphragm may be within the pressure band formed by the sling and clasp fibers of the gastric cardia (i.e. within the distal component of the EGJ, see appendix I). For these reasons more reliable measurements may be obtained using a gastric reference placed well within the gastric body (see also discussion re: marker position in hiatus hernia).

EGJ marker positions

ManoView recognizes the upper and lower esophageal sphincters by identifying the upper and lower high pressure zones. UES markers are placed automatically at the upper border of the sphincter and at the point of maximum resting pressure. The principle LES marker is placed automatically at the point of maximum resting pressure and the upper and lower LES markers at the respective borders of the sphincter [**figure normal EGJ markers**]. Manual adjustment may be required if sphincter pressures are low. Manual placement is always required for the pressure inversion point (PiP) that marks the transition from the abdominal to the thoracic cavity. *In the original version of ManoView* the PiP was located in the line plot view by dragging the principle LES marker across the EGJ barrier placing the PiP marker where variation in pressure with respiration changes from abdominal to a thoracic profile. *In the most recent version* this manoeuvre is possible without leaving the spatiotemporal plot.

The placement of EGJ markers and e-sleeve markers in the presence of a hiatus hernia (defined by separation of the intrinsic and diaphragmatic components) requires some consideration [**figure hiatus hernia EGJ markers I and II**]. In general the principle LES marker is placed at the level of the intrinsic LES pressure band with the upper and lower LES markers either side. Manoview reports the size of the hiatus hernia as the distance between the lower LES border and the PIP* (usually at the diaphragmatic pressure band). The gastric reference usually remains in the intra-abdominal stomach; however in this situation LES pressure may be reported as negative

* If markers are placed above and below the hiatus hernia the LES length reported by ManoView will include the hiatus hernia and this is clearly not correct. The e-sleeve can be used to record pressure across the whole EGJ.

(i.e.; *below* gastric reference pressure) because the intrinsic LES is weak and situated in a negative pressure environment. Moreover the nadir LES pressure can be higher than the resting LES pressure because of raised intra-bolus pressure as peristalsis drives the bolus across the EGJ. In clinical practice these findings indicate that the reflux barrier is ‘incompetent’. However if these findings cause confusion, the ‘problem’ can be addressed by positioning the e-sleeve across the intrinsic LES and placing the gastric reference in the intra-thoracic stomach.

E-Sleeve

Use of the e-sleeve provides a single measurement of EGJ function that compliments the measurements described above and will be familiar to those using conventional manometry. As for perfused ‘Dentsleeve’ sensors the e-sleeve record displays the maximum pressure along the length of the ‘sleeve’. If the e-sleeve is in use ManoView will present e-sleeve measurements in the report, if not the program will present the pressure measurements at the level of the principle LES marker. For normal subjects e-sleeve markers are placed either side of the EGJ [**figure normal EGJ markers**]. As discussed above, in hiatus hernia e-sleeve markers are placed *either* at the upper border of the intrinsic LES and below the diaphragmatic LES (i.e.; includes hiatal sac) *or* either side of the intrinsic LES [**figure hiatus hernia reference options**]. Pressure measurements by e-sleeve are slightly higher than conventional sleeve sensors because (i) mechanical damping is less for solid state sensors and (ii) HRM is sensitive to intra-bolus pressures operating across the EGJ. This is the reason that the nadir LES pressure is often 6-12mmHg (rather than <8mmHg as reported by conventional measurements).

Esophageal marker positions

In the line plot view ManoView displays data from three ‘landmark reference’ channels at 5, 9 and 13cm intervals above the principle LES marker by default. Pressure recorded from these channels is displayed in the line plots. In addition the contractile pressure and velocity of peristalsis between these channels is included in the report. The line plot displays pressure measurements from fixed positions above the LES presents the data in an identical manner to conventional manometry; however fixed positioning provides misleading results in the ‘short esophagus’, in patients with focal spasm and other regional abnormalities of esophageal function. If such abnormalities are noted on the spatiotemporal display then ManoView allows free

positioning of up to five esophageal line plots to be displayed [**figure fixed vs. free line plot positioning**]. Appropriate positioning of the landmark reference channels can make sure that the contractile pressure and velocity from the three esophageal segments is presented in the report.

Temporal and pressure resolution

ManoView allows the practitioner to view the data on a variety of time bases. An overview allows the technical progress of the procedure to be assessed (e.g.; shifts in catheter position). Sections of the record can be viewed to view transient LES relaxation and reflux events or to view the change in motor function in response to a challenge (e.g.; liquid vs. solid swallows). Short time bases are used to analyze single swallows in detail [**figure temporal resolution**].

Variable pressure resolution and the application of isobaric contours to the spatiotemporal plot allow the practitioner to focus attention on different aspects of esophageal function.

Conventional manometry focuses attention on peristalsis and the EGJ; however it is known that contractile pressure is not closely coupled to the development of an effective intra-bolus pressure gradient (the force that drives bolus transport) or reflux barrier.⁷ HRM can bring both aspects of esophageal function into vivid relief. Adjusting pressure resolution allows the practitioner to visualize the segmental function and coordination of esophageal peristalsis (at relatively high pressures) *and then* to assess whether an effective pressure gradient is produced by this activity (at relatively low pressures) [**figure peristalsis pressure resolution**]. Most authors define ‘esophageal dysmotility’ on the basis of contractile pressure <30 mmHg;⁸ however studies with concurrent HRM and videofluoroscopy show that hypotensive contractions are consistent with normal function if peristaltic coordination is preserved and a positive pressure gradient from the is maintained from the pharynx to the stomach. In contrast poor coordination (e.g.; a wide ‘proximal transition zone’ between the proximal and mid-esophagus) or focal spasm in the smooth muscle esophagus can disrupt bolus transport despite normal contractile pressures.³

Similarly although there is an association between low LES pressure and esophageal acid exposure, it is disruption of the EGJ (i.e.; separation of the intrinsic and diaphragmatic components of the LES) that has the greatest impact on the competence of the reflux barrier.⁹ In addition the ability to monitor esophageal, EGJ and gastric intra-luminal pressure means that

HRM is at least as accurate as sleeve sensor manometry for the detection of transient LES relaxations and other events that compromise the reflux barrier.¹⁰

Contour plots and the assessment of intra-luminal pressure gradients

ManoView provides two additional methods by which the coordination of peristalsis and development of an effective intra-bolus pressure gradient can be assessed. Firstly contour plots can be superimposed on the spatiotemporal plot at any pressure. Secondly the panel to the right of the spatiotemporal plot reveals the intra-luminal pressure from the pharynx to the stomach at a given time (marked by the red cursor). If pressure resolution is focused on lower pressures these tools reveal the build up of intra-bolus pressures by peristalsis and the moment when the pressure gradient is sufficient to overcome the resistance to flow across the EGJ and into the stomach. If pressure resolution is focused on higher pressures these tools reveal the segmental functional anatomy of peristalsis and highlight abnormally high contractile pressures [**figure pressure resolution**]. Similarly it is possible to document unstable EGJ anatomy and transient LES relaxation that underlie belching and reflux events in exquisite detail [**figures unstable EGJ, figure TLESR with reflux**]

Smart Mouse

Further, detailed analysis of pressure measurements displayed by ManoView can be performed using the Smart Mouse. Once activated in the tools drop-down menu the basic smart mouse displays the pressure and distance from the nares at any point on the spatiotemporal plot. Using the right click and dragging the mouse across the screen provides the distance in time and space, the gradient (e.g.; peristaltic velocity) and pressure information between two points [**figures smart mouse basic**]. The portable sleeve is an additional feature of the smart mouse that graphically displays the same information [**figures smart mouse incl. portable sleeve**].

.

.

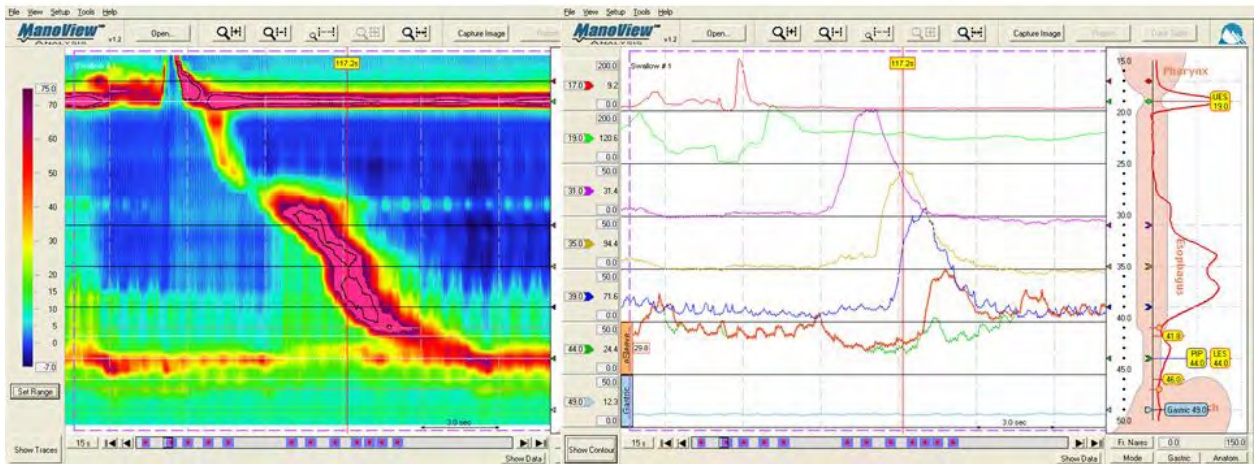
ManoView analysis of HRM data

Analysis of HRM data with ManoView is easy and quick but also comprehensive.

- 1. EGJ markers are set by interrogating the baseline measurement.**
- 2. Esophageal markers are positioned as appropriate.**
- 3. Temporal and Pressure resolution are set to provide the best possible overview of the data (depending on the focus of interest and contractile pressures).**
- 4. Swallows are examined in sequence. Measurement frames can be adjusted, added or removed as appropriate (e.g.; for technical reasons, repeated swallowing).**
- 5. Additional swallows or maneuvers (e.g.; large volume swallow) are examined. In addition events surrounding symptom events can be included in the report by screen capture.**
- 6. Analysis is commenced by clicking on the check box in the baseline measurement frame.**
- 7. Each frame is checked again to ensure that the analysis has proceeded appropriately and the automatic placement of supplemental markers is checked (for the analysis of LES relaxation, peristaltic velocity and contractile pressure).**
- 8. Data for inclusion in the report is checked. The screen shots of swallows to be included in the report are selected (it is recommended to include line plots as well as spatiotemporal plots to aid those unfamiliar with HRM)**
- 9. The data is embedded in the report template, a Microsoft Word document.**
- 10. The report is completed by the practitioner.**

Figure: normal peristalsis

The spatiotemporal plot reveals the segmental nature of esophageal peristalsis and the coordination between the pharyngeal, proximal-, mid- and distal-esophageal contractions. Each segment can be defined in terms of the rise and fall of contractile pressure and changes in peristaltic velocity. In this example the contour plot highlights the mid- and distal-peristaltic contractions and the cursor at the transition zone between the mid- and distal contractions reveals a double peak (far right panel) representing the death of the mid-esophageal contraction and the birth of the distal contraction. None of this is visible in the line plots.



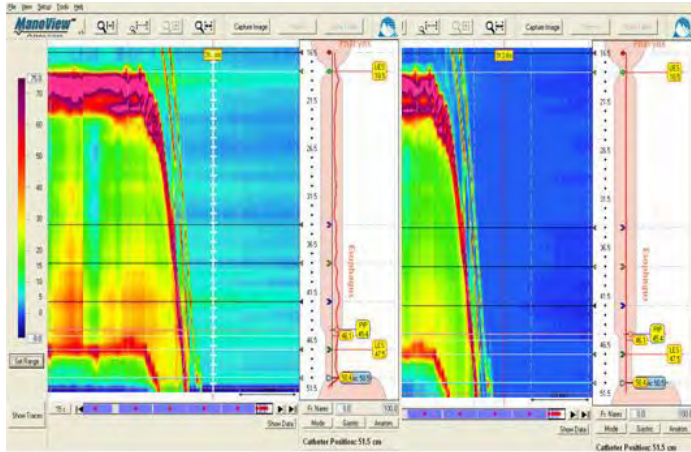


Figure calibration

Thermal calibration is most accurate when performed immediately after the catheter is removed. In addition, as in this example, after a long study a small amount of measurement drift can be seen in several pressure channels (left panel). The cursor is positioned immediately after withdrawal and click Tools>Set Thermal Calibration corrects both thermal and measurement drift.

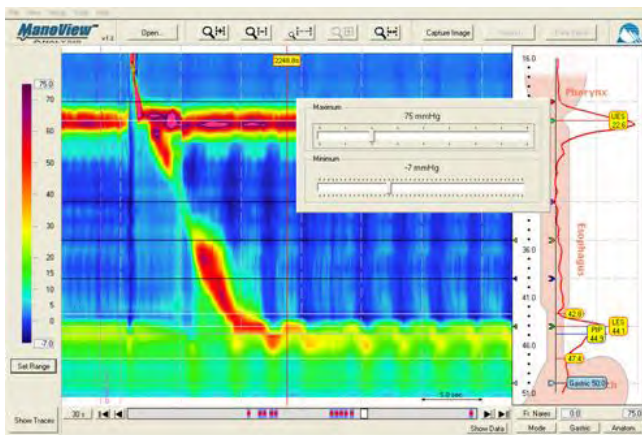
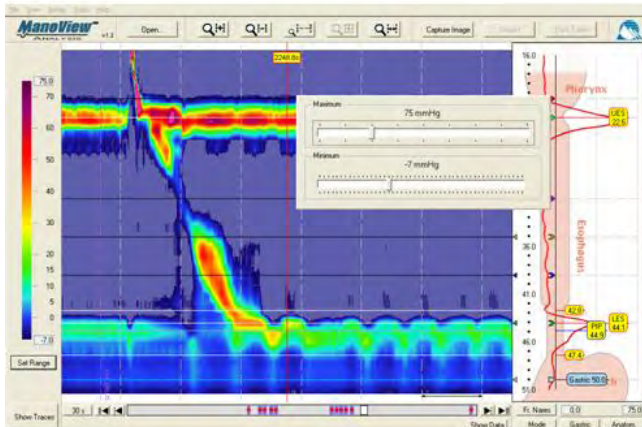


Figure gastric vs. atmospheric reference

Essentially the same information is provided using gastric (A) and atmospheric (B) reference; however the appearance is somewhat different because firstly gastric pressure is above atmospheric pressure and secondly gastric pressure will vary with respiration, position and other manoeuvres.



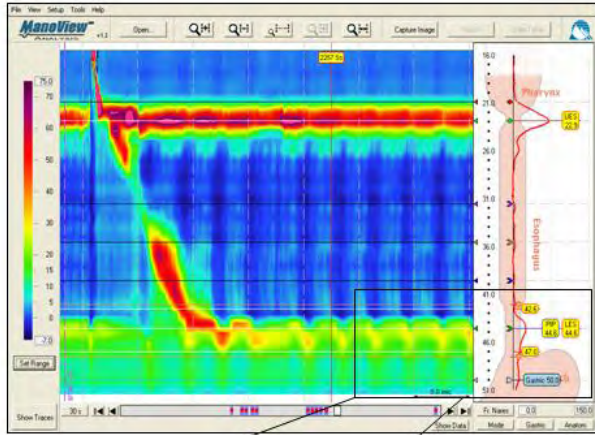
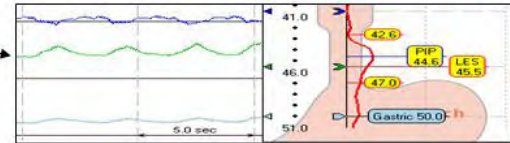
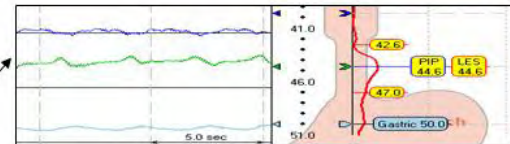
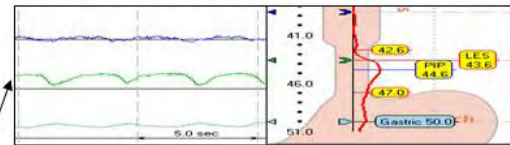
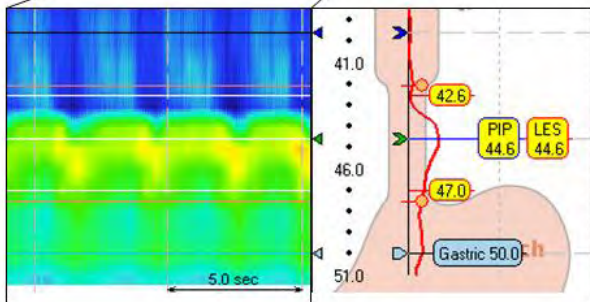


Figure: Normal EGJ markers

The EGJ is represented by a single pressure zone. The principle LES marker is placed at the peak pressure (in expiration), upper and lower LES markers at the inflexion points and the e-sleeve markers slightly further apart to allow for the rise and fall with respiration. The pressure inversion point is located by moving the principle LES marker across the high pressure zone to locate the transition between the two body cavities.



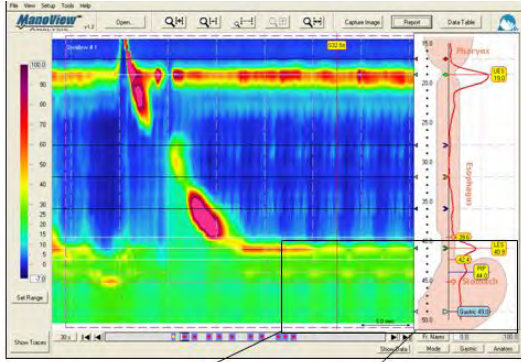
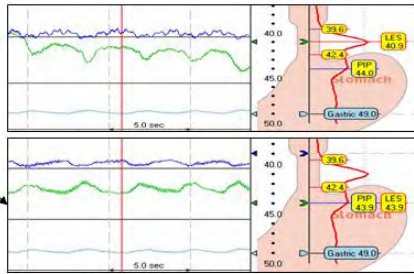
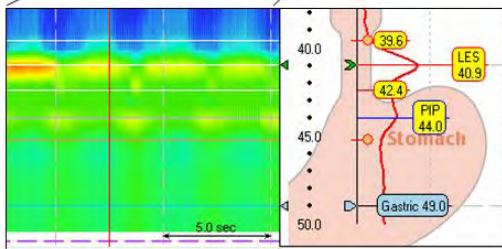


Figure Hiatus hernia markers I

The EGJ is represented by double pressure zones about 4cm apart. The principle LES marker is placed at the peak proximal pressure band (intrinsic LES). The upper and lower LES markers are placed either side of the proximal LES. The pressure inversion point (PIP) is at the distal LES band (i.e.; diaphragm). Both are located by moving the principle LES marker across the high pressure zone. In the ManoView report LES length is between the upper and lower LES markers and the length of the hiatus hernia is from the lower LES marker to the PIP.

Recommended



#

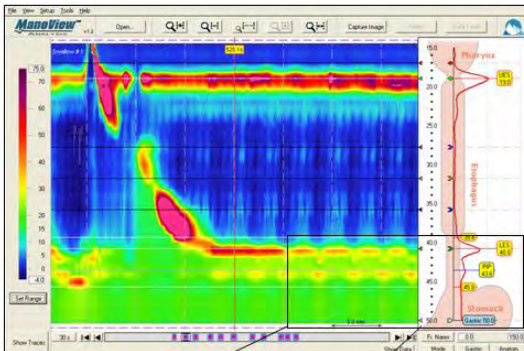
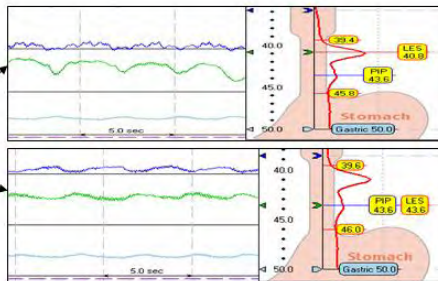
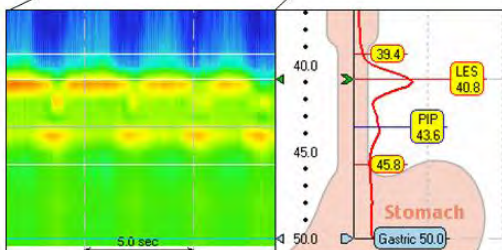


Figure Hiatus hernia markers II

The EGJ is represented by double pressure zones about 4cm apart. The principle LES marker is placed at the peak proximal pressure band (intrinsic LES). The pressure inversion point is at the distal band (i.e.; diaphragmatic LES). Here the upper and lower LES markers are placed either side of the double band. However if this is done the hiatal sac is included in the LES and the ManoView report *will not* record the presence of an hiatus hernia.

Not Recommended



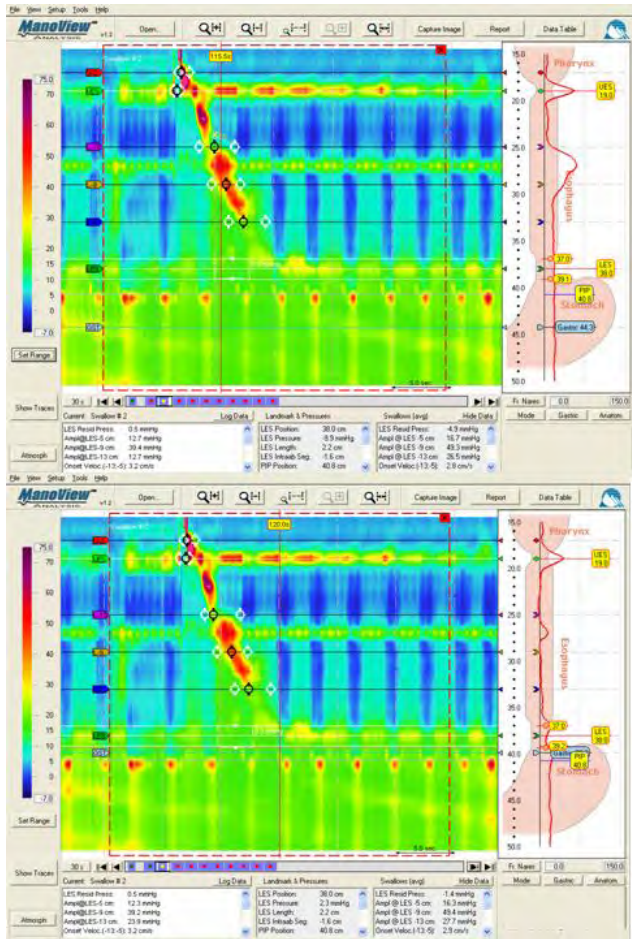


Figure: hiatus hernia reference options

This patient with reflux and regurgitation has weak esophageal peristalsis and a large hiatus hernia. The intrinsic LES is seen most clearly in the post-contraction phase during expiration. The 'diaphragmatic pinch' is seen during inspiration.

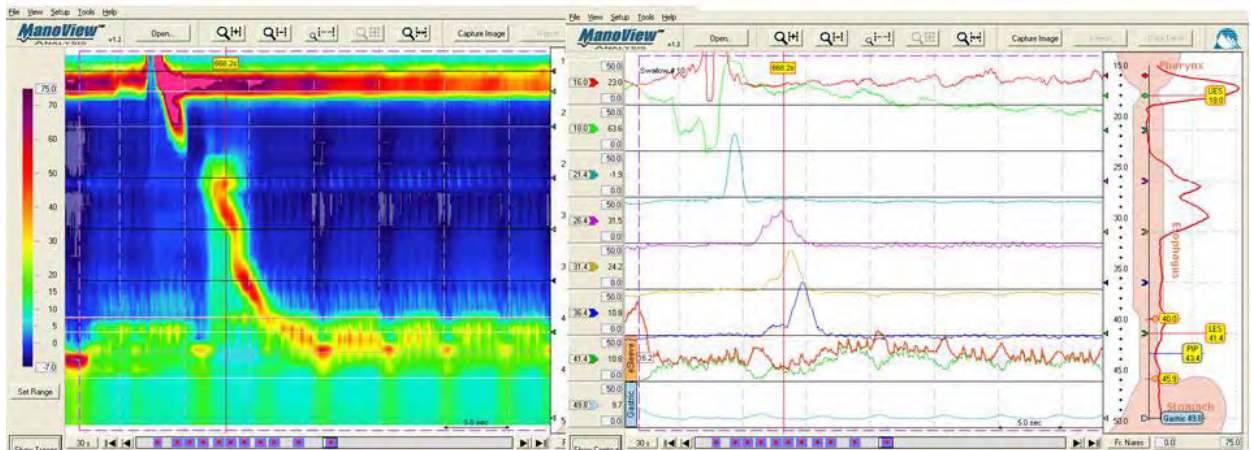
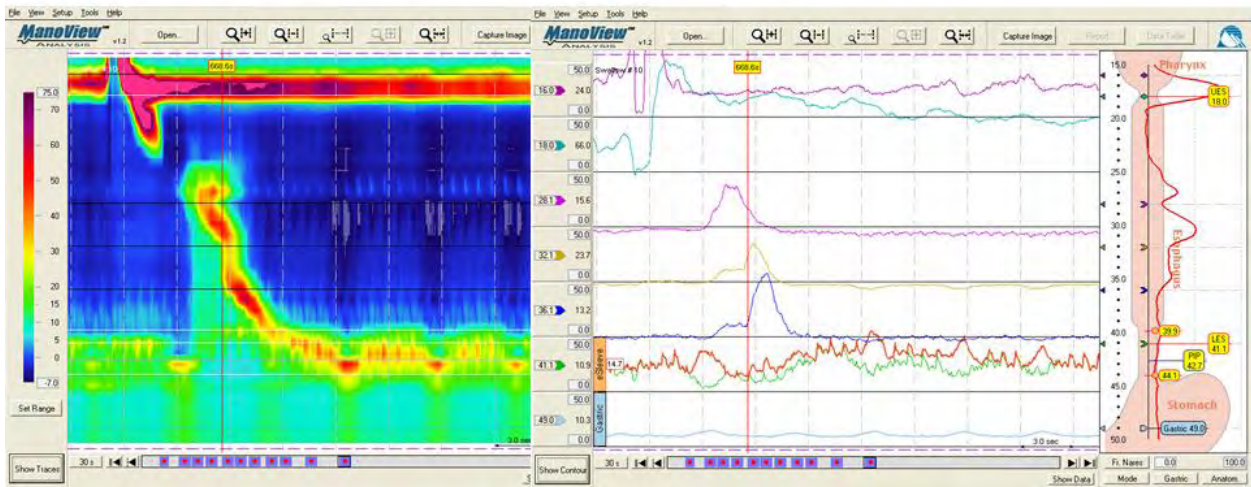
Placing the gastric reference in the intra-abdominal stomach results in a negative LES resting pressure (-9.9mmHg) because the intrinsic LES is weak and in the negative pressure environment of the thorax. Moreover the residual, nadir LES pressure on swallowing is *higher* than resting LES pressure (0.5mmHg) because of the raised intra-bolus pressure on swallowing.

Placing the gastric reference in the intra-thoracic stomach results in a positive resting pressure (+2.3mmHg) and the residual, nadir LES pressure on swallowing is *lower* than resting LES pressure (i.e., documents LES relaxation).

Figure: fixed vs. free line plot positioning

The separate proximal, mid- and distal segmental contractions that make up esophageal peristalsis are well seen in this patient with reflux and occasional regurgitation. These contractions occur in sequence and a positive intra-bolus esophago-gastric pressure gradient is present (predicts effective bolus transport)

Using the line plots at the 'fixed' default positions at 3, 9 and 13cm above the principal LES marker simultaneous contractions were reported in 50% of swallows because the first two markers were positioned at the distal transition between the mid- and distal peristaltic contractions. 'Free' positioning of sensors at 5, 10, 15 and 20cm above the principal LES marker provided a more appropriate assessment of esophageal peristalsis by matching the sensors to the segmental contractions.



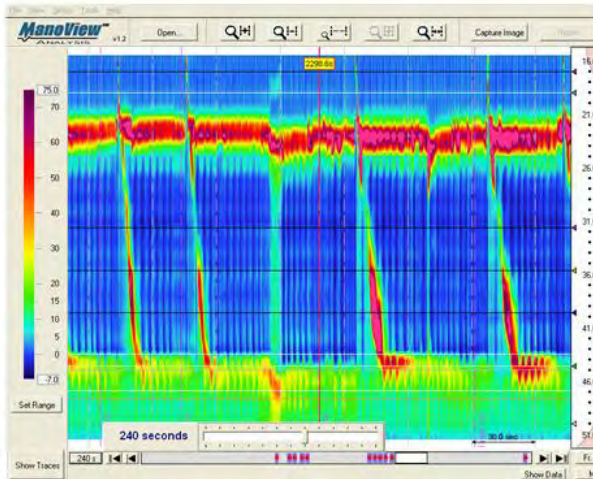
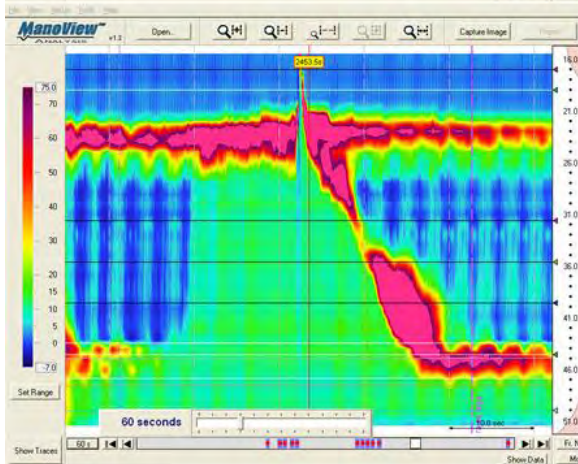
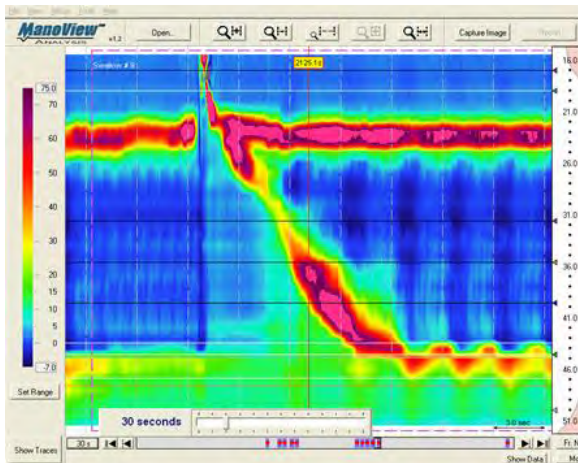
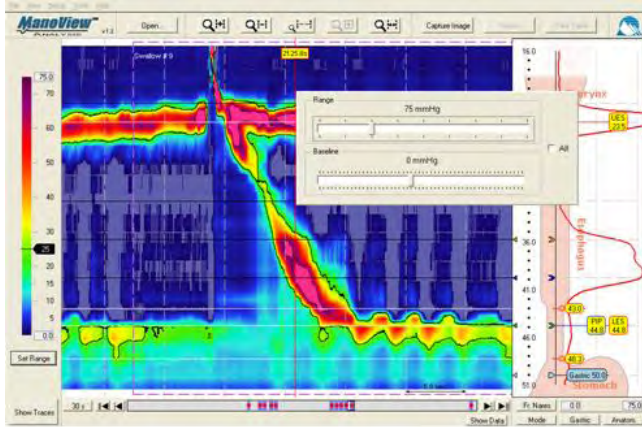


Figure: temporal resolution

ManoView allows the temporal resolution to be altered between 15 and 1200s. Short time windows allow individual swallows to be studied in detail. Intermediate time windows allow the motor activity 'around' a symptom event to be assessed. Longer time windows provide an overview of the study and are useful to examine the reproducibility of motor response to a physiologic challenge (e.g.; response to liquid and solid volume swallows).



At intermediate and higher pressures the 'topography' of the peristaltic contractions becomes evident. The choice of pressure range is dictated by the contractile pressure of peristalsis.

C: The proximal transition zone is well seen at intermediate pressures. Here the contour plot highlights that a contractile pressure of >25mmHg is maintained from the pharynx to the stomach.

D: The segmental character of esophageal peristalsis is evident at intermediate to higher pressures. Here the contour plot reveals the separate mid- and distal esophageal contractions in the smooth muscle esophagus.

E: Intra-bolus and LES pressures are not well seen at very high pressures; however abnormally high contractile pressures (e.g.; >180mmHg as highlighted by contour plot), are easy to detect. In this patient chest discomfort was associated with high pressure, long duration contractions following solid bolus and repeated water swallows (as here).

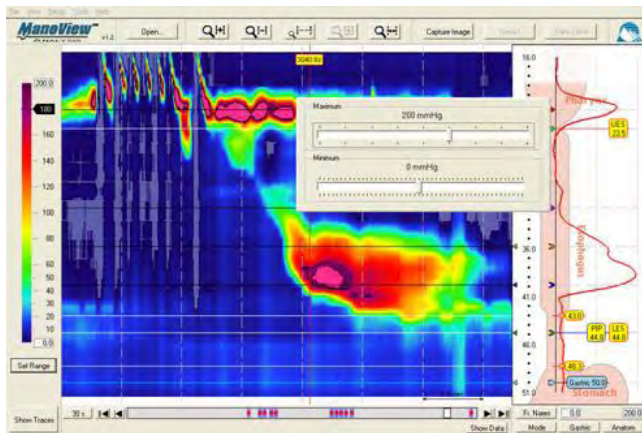
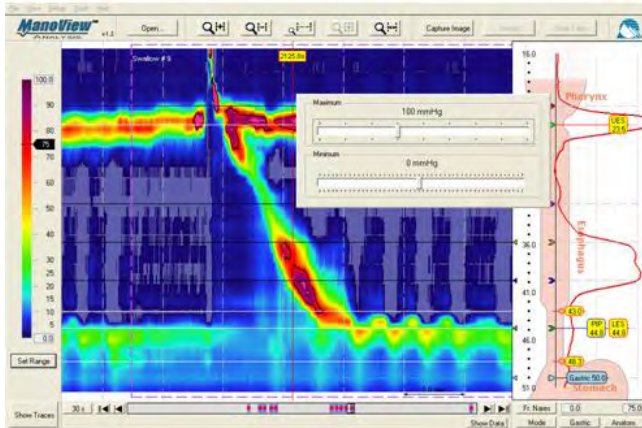
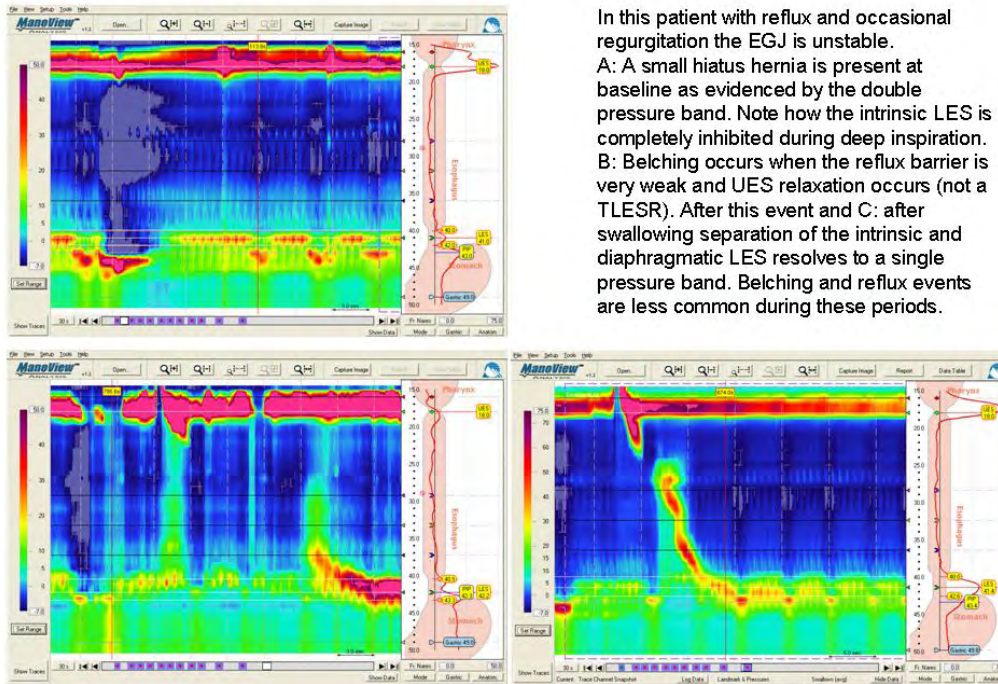
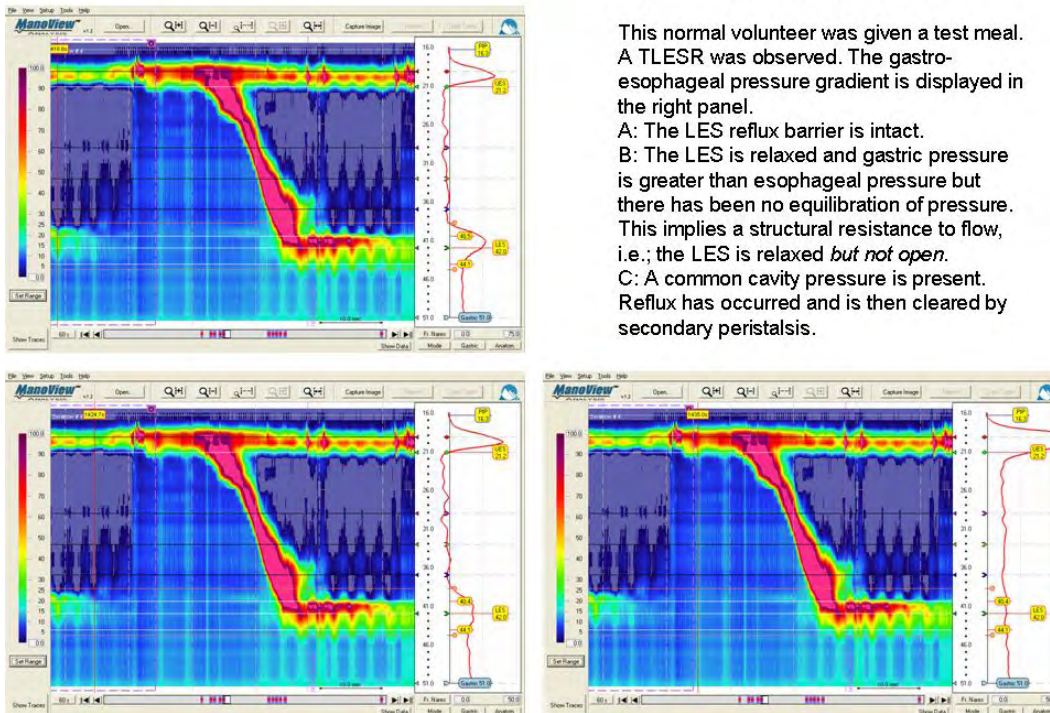


Figure: Unstable EGJ



In this patient with reflux and occasional regurgitation the EGJ is unstable.
 A: A small hiatus hernia is present at baseline as evidenced by the double pressure band. Note how the intrinsic LES is completely inhibited during deep inspiration.
 B: Belching occurs when the reflux barrier is very weak and UES relaxation occurs (not a TLESR). After this event and C: after swallowing separation of the intrinsic and diaphragmatic LES resolves to a single pressure band. Belching and reflux events are less common during these periods.

Figure: TLESR with reflux



This normal volunteer was given a test meal.
 A TLESR was observed. The gastro-esophageal pressure gradient is displayed in the right panel.
 A: The LES reflux barrier is intact.
 B: The LES is relaxed and gastric pressure is greater than esophageal pressure but there has been no equilibration of pressure. This implies a structural resistance to flow, i.e.; the LES is relaxed *but not open*.
 C: A common cavity pressure is present. Reflux has occurred and is then cleared by secondary peristalsis.

Figure: smart mouse basic

This patient complained of chest pain on swallowing solids. Symptoms were associated with a wide proximal transition zone between the proximal and mid-esophageal contractions and focal spasm in the mid-esophagus (a combination likely to cause bolus escape). Here the smart mouse is used to measure the characteristics of the transition zone mid-esophageal and distal-esophageal by dragging the arrow across each region in interest in turn while holding down the right mouse button.

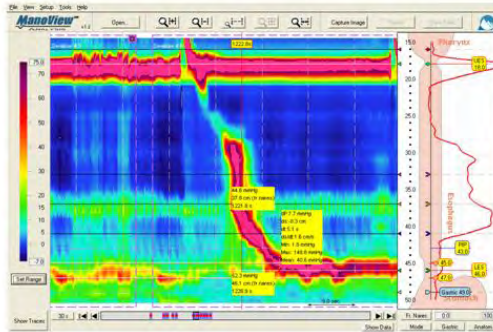
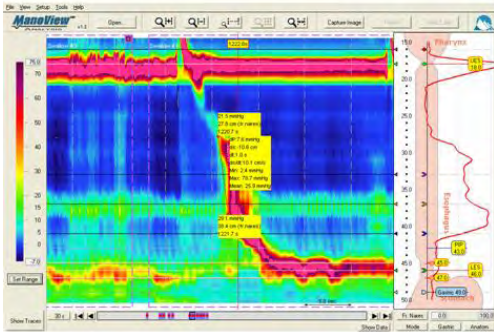
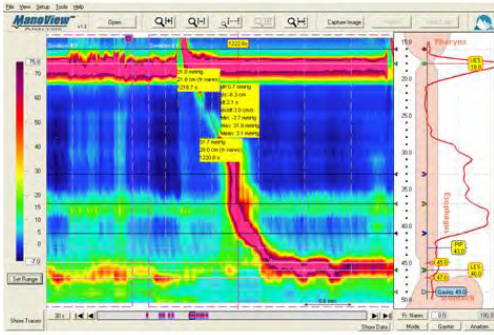
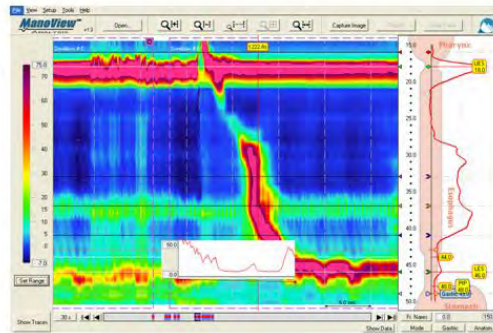
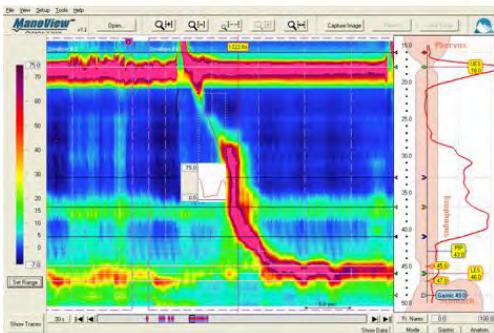
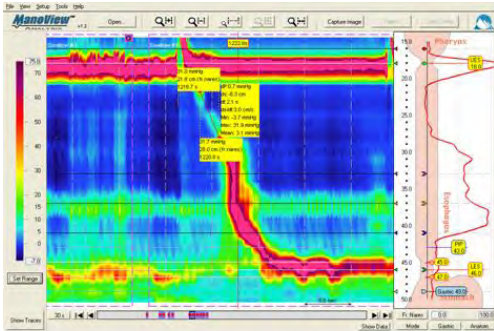


Figure: smart mouse including portable sleeve

To interrogate the proximal transition zone further the portable sleeve function can be activated. This technique complements the basic smart mouse function by demonstrating graphically
 A: the wide (>3cm), deep (nadir pressure <5mmHg) proximal transition zone.
 B: preserved LES relaxation

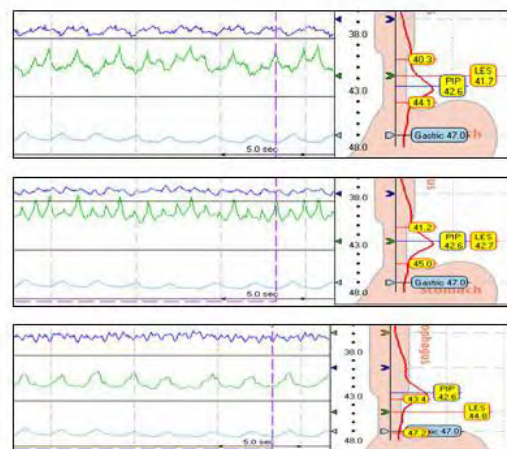
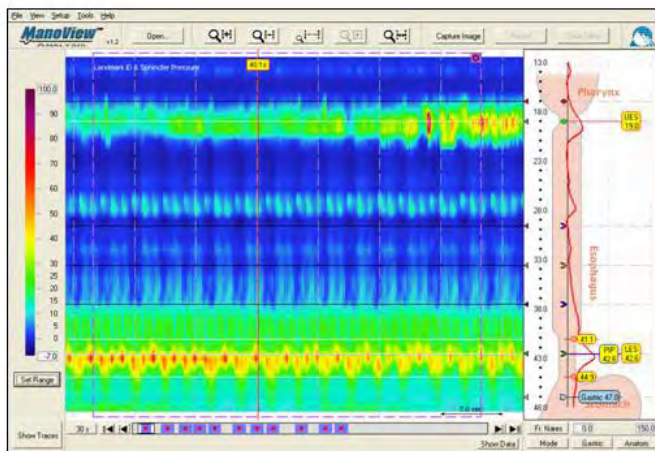


ManoView analysis of HRM data

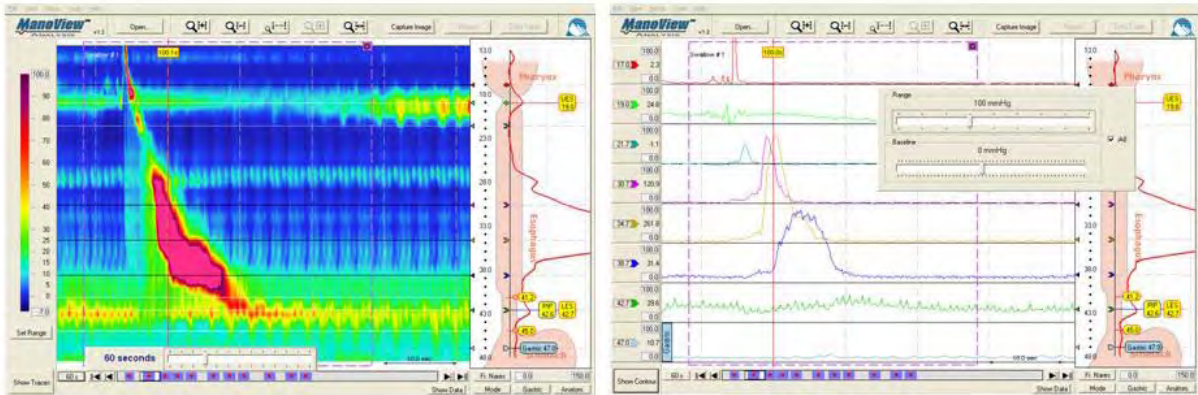
Analysis of HRM data with ManoView is easy and quick but also comprehensive.

1. EGJ markers are set by interrogating the baseline measurement.
2. Esophageal markers are positioned as appropriate.
3. Temporal and Pressure resolution are set to provide the best possible overview of the data (depending on the focus of interest and contractile pressures).
4. Swallows are examined in sequence. Measurement frames can be adjusted, added or removed as appropriate (e.g.; for technical reasons, repeated swallowing).
5. Additional swallows or maneuvers (e.g.; large volume swallow) are examined. In addition events surrounding symptom events can be included in the report by screen capture.
6. Analysis is commenced by clicking on the check box in the baseline measurement frame.
7. Each frame is checked again to ensure that the analysis has proceeded appropriately and the automatic placement of supplemental markers is checked (for the analysis of LES relaxation, peristaltic velocity and contractile pressure).
8. Data for inclusion in the report is checked. The screen shots of swallows to be included in the report are selected (it is recommended to include line plots as well as spatiotemporal plots to aid those unfamiliar with HRM)
9. The data is embedded in the report template, a Microsoft Word document.
10. The report is completed by the practitioner.

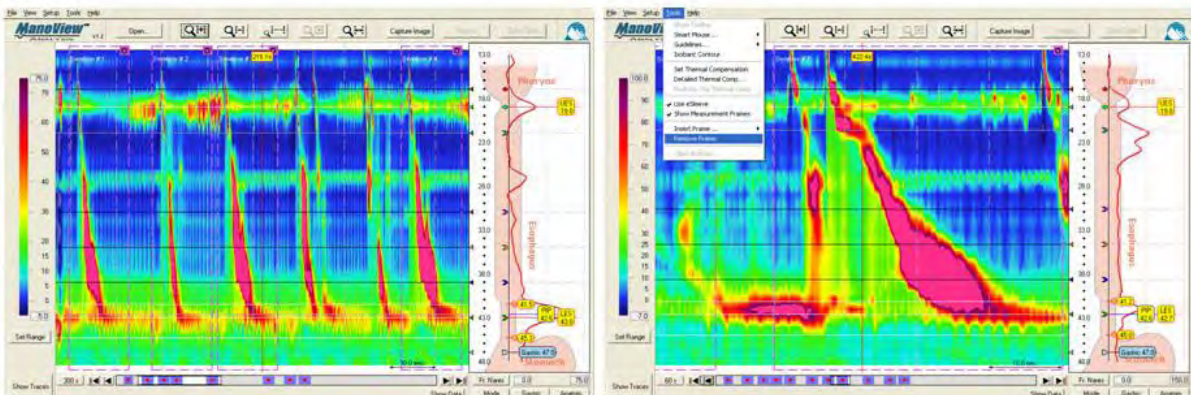
1. EGJ markers are set by interrogating the baseline measurement by passing the principal LES marker across the high pressure zone.



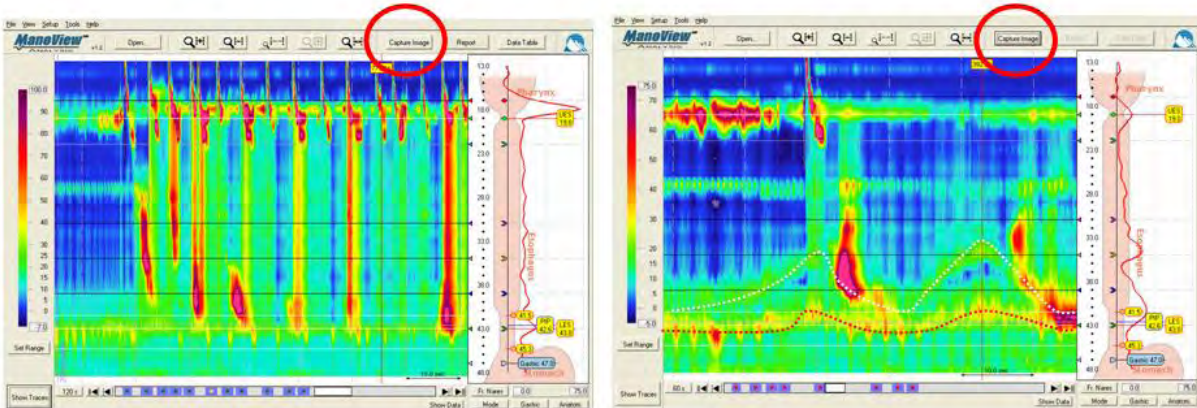
2. Esophageal markers are positioned as appropriate to allow an assessment of the proximal, mid- and distal peristaltic contractions on the line plot view (the data in the report is also calculated using these markers).
3. Temporal and Pressure resolution are set to provide the best possible overview of the data in the spatiotemporal plot



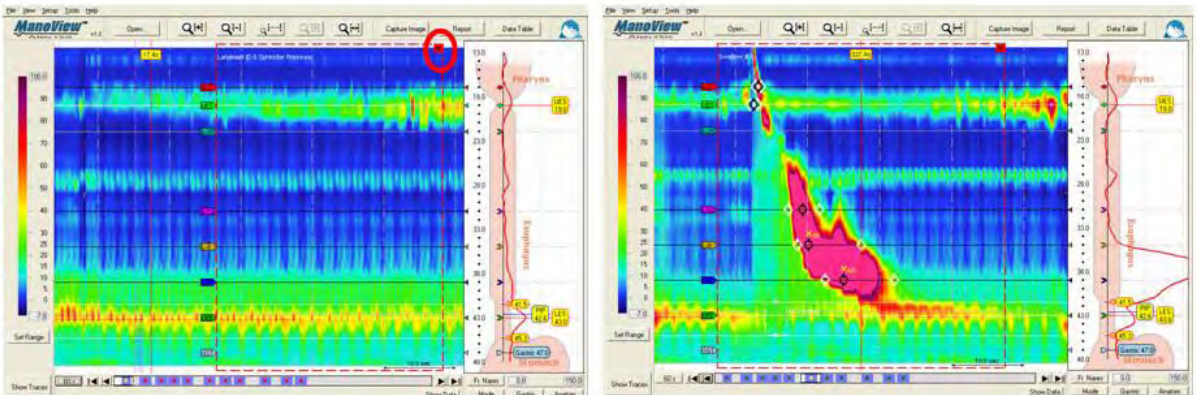
4. Swallows are examined in sequence. Measurement frames can be adjusted, added or removed as appropriate (e.g.; for technical reasons, repeated swallowing).



- Additional swallows or maneuvers (e.g.; large volume swallow) are examined. In addition events surrounding symptom events can be included in the report by screen capture.



- Analysis is commenced by clicking on the check box in the baseline measurement frame.
- Each frame is checked again to ensure that the analysis has proceeded appropriately and the automatic placement of supplemental markers is checked (for the analysis of LES relaxation, peristaltic velocity and contractile pressure).



References

1. Staiano A, Clouse RE. Detection of incomplete lower esophageal sphincter relaxation with conventional point-pressure sensors. *Am J Gastroenterol* 2001;96:3258-67.
2. Ghosh SK, Pandolfino JE, Zhang Q, Jarosz A, Shah N, Kahrilas PJ. Quantifying esophageal peristalsis with high-resolution manometry: a study of 75 asymptomatic volunteers. *Am J Physiol Gastrointest Liver Physiol* 2006;290:G988-97.
3. Fox M, Hebbard G, Janiak P, Brasseur JG, Ghosh S, Thumshirn M, Fried M, Schwizer W. High-resolution manometry predicts the success of oesophageal bolus transport and identifies clinically important abnormalities not detected by conventional manometry. *Neurogastroenterol Motil* 2004;16:533-42.
4. Clouse RE, Staiano A, Alrakawi A, Haroian L. Application of topographical methods to clinical esophageal manometry. *Am J Gastroenterol* 2000;95:2720-30.
5. Tutuian R, Castell DO. Combined multichannel intraluminal impedance and manometry clarifies esophageal function abnormalities: study in 350 patients. *Am J Gastroenterol* 2004;99:1011-9.
6. Pandolfino JE, El-Serag HB, Zhang Q, Shah N, Ghosh SK, Kahrilas PJ. Obesity: a challenge to esophagogastric junction integrity. *Gastroenterology* 2006;130:639-49.
7. Brasseur JG, Dodds WJ. Interpretation of intraluminal manometric measurements in terms of swallowing mechanics. *Dysphagia* 1991;6:100-19.
8. Spechler SJ. AGA technical review on treatment of patients with dysphagia caused by benign disorders of the distal esophagus. *Gastroenterology* 1999;117:233-54.
9. Bredenoord AJ, Weusten BL, Timmer R, Smout AJ. Intermittent spatial separation of diaphragm and lower esophageal sphincter favors acidic and weakly acidic reflux. *Gastroenterology* 2006;130:334-40.
10. Bredenoord AJ, Weusten BL, Timmer R, Smout AJ. Sleeve sensor versus high-resolution manometry for the detection of transient lower esophageal sphincter relaxations. *Am J Physiol Gastrointest Liver Physiol* 2005;288:G1190-4.