

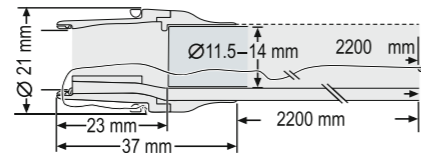
# FTRD® System Set

consisting of:

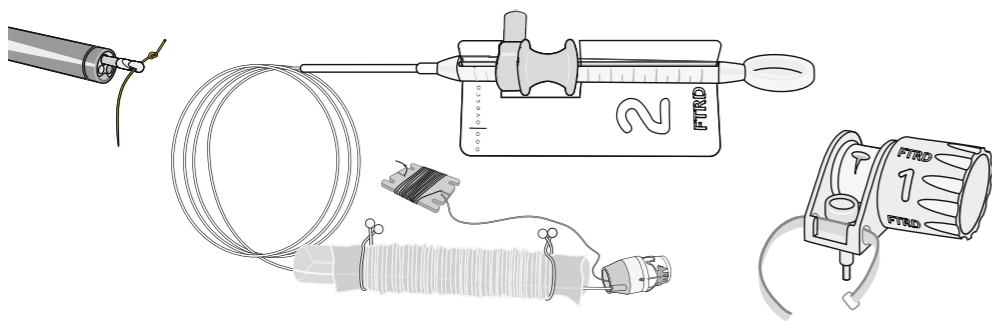
(Reference number 200.70)

## Details and components

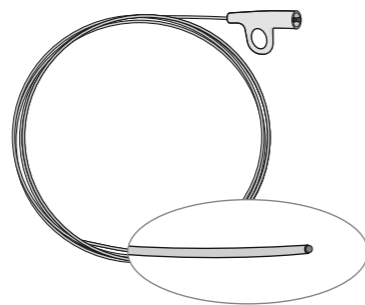
Key dimensions of the FTRD applicator cap:  
Working channel diameter: 3.2 mm



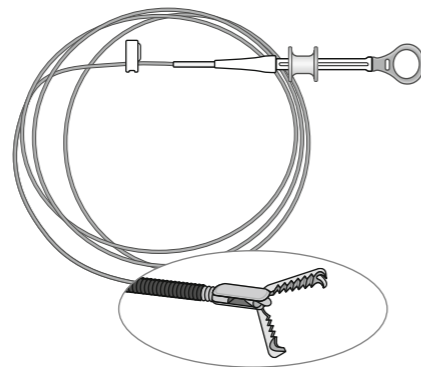
The FTRD System consists of the FTRD applicator cap coming with a ready-to-use mounted FTRD clip and a fitted HF snare at its tip. Included are the hand wheel, thread retriever for easy retrieval of the release thread, and the endoscope sleeve. The applicator cap is being mounted on the endoscope with the snare running on the outside of the scope, the sleeve preventing entrapment of any tissue between scope and snare. By turning the wheel the clip will be released through the thread and a new release ring. The target tissue will be firmly immobilized and subsequently cut by the closed snare. The FTRD System is only available in one size, for endoscopes with a diameter of 11.5 –14 mm.




HF coagulation probe for marking of the target lesion in preparation of FTRD use. Marking the lesion will facilitate both detection and complete resection of the right tissue.  
Flexible shaft, length 220 cm



Grasping forceps for proper grip on the target tissue and precise retrieval of the sample into the applicator cap.  
Flexible shaft, length 220 cm

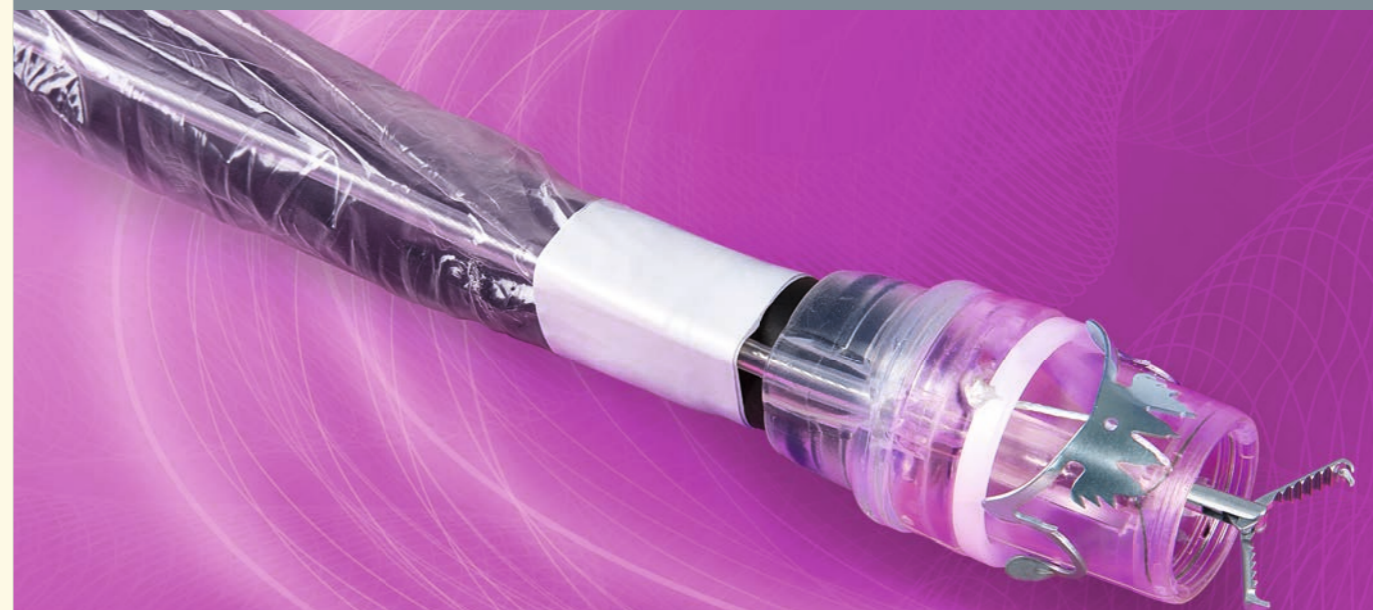

ovesco  
innovation in scope



# FTRD® System

Full-Thickness Resection Device for flexible endoscopy



Ovesco Endoscopy AG  
Dorfackerstr. 26  
72074 Tuebingen/Germany

Phone +49 (0) 7071.96528-160  
Fax +49 (0) 7071.96528-260  
service@ovesco.com

Ovesco Endoscopy USA Inc.  
455 Los Gatos Blvd.  
Suite 101  
Los Gatos, CA 95032  
USA

Phone +1 408 884 8976  
Fax +1 408 608 2077  
customerservice@ovesco-usa.com

[www.ovesco.com](http://www.ovesco.com)

FTRD® System English version 2 | 2014-09-30

Ovesco Endoscopy AG is a medical device company specializing in the fields of flexible endoscopy and endoluminal surgery. Ovesco develops, manufactures, and markets innovative products for the treatment of gastrointestinal disease. Ovesco products stand for therapeutic efficacy and efficient application.



**The novel FTRD® System for endoscopic Full-Thickness Resection (eFTR) of lesions in the colon and rectum.**

- Fast transluminal minimally invasive technique
- Proven OTSC® technology for safe tissue closure
- Minimal thermal injury
- Valid histologic evaluation of one en-bloc specimen according to residual tumor (R) classification
- Complete instrument set for endoscopic full-thickness resection procedures



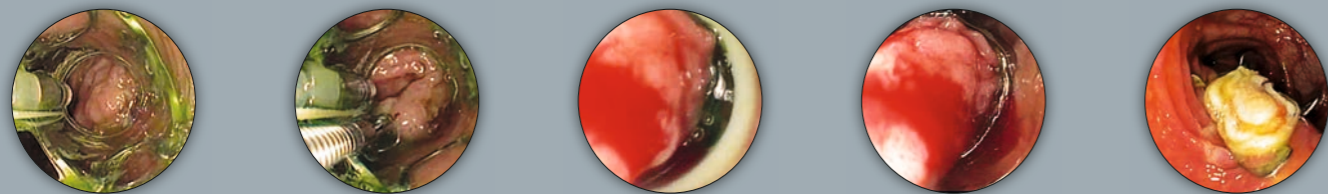
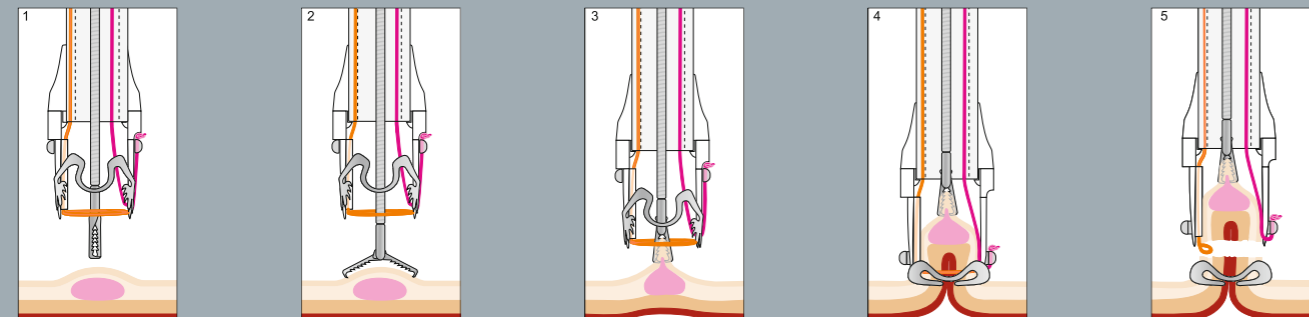
**FTRD® System Set**

Full-Thickness Resection Device for flexible endoscopy

The FTRD® System Set is a novel tool for diagnostic and therapeutic full-thickness resection via the flexible endoscope in the colon and rectum. The technology is based on the well-established OTSC® System, enabling the endoscopist to resect all layers of suitable lesions including the serosa. The design of the FTRD® System ensures that the transection of the tissue happens only after the defect has been closed completely. At no time will abdominal cavity and bowel lumen be in contact.

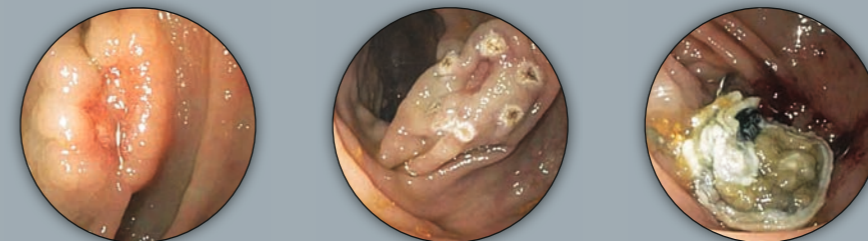
**Procedure**

Stepwise eFTR of a recurrent sessile adenoma (non-lifting sign) in the descending colon.\*



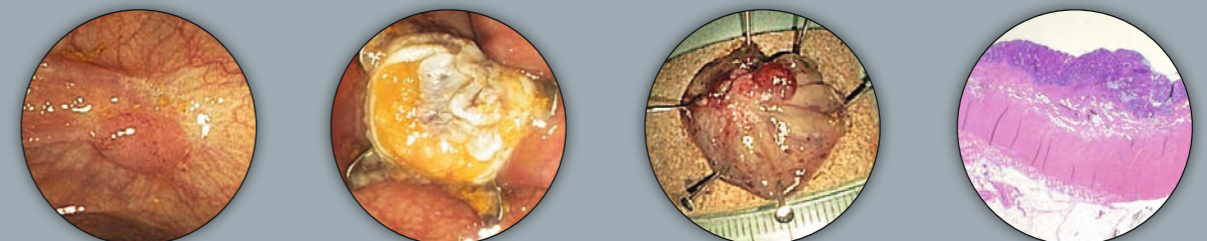
1. Marking of the lesion before mounting the FTRD System
2. Grasping of the target tissue with the FTRD Grasper
3. Retrieval of the target tissue within cap and fixation
4. Double check whether target tissue is completely within the FTRD Cap – Release of clip with hand wheel
5. Closure of snare and electrical cut of target tissue. Retrieval of the resected sample. Check of the resection site

Example 2: De novo resection after incomplete polypectomy in the descending colon (early carcinoma)\*



- Status after incomplete polypectomy in the descending colon (early carcinoma)
- Tissue marked with electrical probe
- Resection site after FTRD procedure (tissue previously marked with Indian ink)

Example 3: Resection of a relapsed adenoma (HG1EN) in the descending colon (non-lifting sign)\*



- Relapsed adenoma in the descending colon, non-lifting sign
- FTRD resection site: all layers of the bowel wall to be identified in cross section
- Full-thickness sample, ca. 2.5 cm
- Histology: completely resected recurrent adenoma, HG1EN

\* Source: Prof. Dr. K. Caca and Dr. A. Schmidt, Klinikum Ludwigsburg, Dept. of Internal Medicine, Gastroenterology, Hemato-Oncology, Diabetes, and Infectious Diseases